

# ceramic implants

**international magazine of** ceramic implant technology



## **research**

Guided regeneration  
of lamellar bone tissue

## **case report**

Immediate placement  
in the aesthetic zone

## **interview**

Clear trend towards  
metal-free reconstructions

Straumann® PURE Ceramic Implant System  
Discover natural PURE white.  
Love your smile.



Two-piece design available soon



**OUTSTANDING  
ESTHETICS**

Favorable soft tissue attachment, high-end esthetic restorations



**PROVEN  
QUALITY**

High performance zirconia ceramic, 100% proof tested



**EXCEPTIONAL  
SURFACE**

ZLA® surface with revolutionary osseointegration features



**METAL-FREE**

A metal-free alternative to titanium implants



**INNOVATIVE**

A new system that helps you expand your patient pool



Contact your local Straumann representative now or visit  
[pure.straumann.com](http://pure.straumann.com)

Georg Isbaner

Editorial Manager



# Ceramic implants— current state of discussion

Dear Readers,

When the idea for this magazine was first presented at the IDS 2017, it was not yet foreseeable that in the months leading up to the first publication in fall 2017 the developments of the ceramic implant market would yet be speeding up. Numerous dental businesses were introducing new or newly acquired ceramic implant systems. The first publication of *ceramic implants—international magazine of ceramic implant technology* thus occurred in a highly sensitive environment and consequently received much attention.

If one is closely following the discussions regarding ceramic implants of the past months and years—may it be by reading, among others, this magazine or by participating in the specialist congresses e.g. in San Diego, USA (IAOCI), Constance, Germany (ISMI) or at the diverse ITI sessions—certain topics have become especially prominent:

On one hand material and processing characteristics are concerned—taking into account the monoclinic and tetragonal phases of zirconium dioxide ( $\text{ZrO}_2$ )—defining the mechanical and prosthetic capacities of the implant body. As implant material  $\text{ZrO}_2$  can resist extreme loading forces in the tetragonal phase (compared to the monoclinic phase) and its high biocompatibility makes it an ideal dental material. However, owing to its tremendous stiffness in comparison to titanium it is also prone to fractures at the load limit—as has been noticed in the past. This consequently has an influence on the design (production), application and the characteristics of

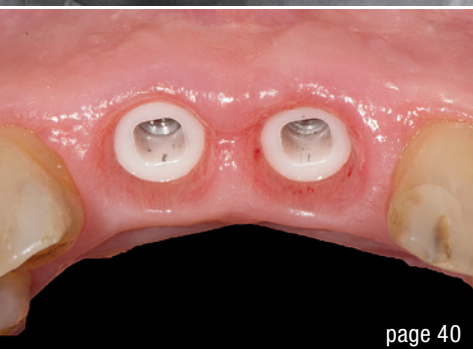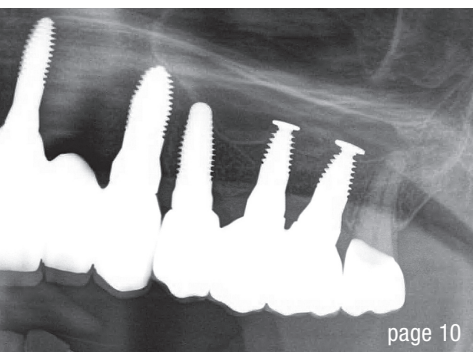
one-piece and two-piece (screw-retained or cemented) implant systems. Thus we are reaching the second discussion topic: One-pieced or two-pieced?

The advantage of one-piece  $\text{ZrO}_2$  implants is the absence of a micro-gap. The experts however recommend—and here the opinions and methods still widely differ—to forego a possible prosthetic follow-up processing by grinding the implant head as it can impair the surface characteristics (tetragonal > monoclinic). Thus, naturally also the indication area is restricted, as the surgically best position does not necessarily lead to the most reasonable prosthetic solution.

According to the experts, also with two-pieced, screw-retained systems, owing to the material solidity of  $\text{ZrO}_2$  and in case of faulty design, there is a risk of fractures or loosening at the implant–abutment connection. Manufacturers of the newest two-piece systems are, however, stating that these risks have been overcome as the design was adjusted accordingly and no significant disadvantages in comparison to two-piece titanium implants have to be feared. Further the prosthetic diversity of two-piece  $\text{ZrO}_2$  systems, especially when combined with thorough digital planning, makes it possible to join the necessary prosthetic solution with the surgically reasonable position of the implant. Overloading and faulty functionality including the presumed fracture risk can be avoided in advance. The newest generation of bone-level  $\text{ZrO}_2$  systems is closing important indication gaps in comparison to titanium systems.

Yours, Georg Isbaner





Cover image courtesy of Straumann AG  
www.straumann.com



## editorial

- Ceramic implants—current state of discussion 03  
Georg Isbaner

## research

- From peri-implantitis to implant disease 06  
Dr Franz-Jochen Mellinghoff, M.Sc., PhD
- Analogous therapy for guided regeneration of lamellar bone tissue 10  
Dr Karl Ulrich Volz, Prof. Dr Dr Ralf Smeets, Dr Martin Chares,  
Dr Stefan König MSc., Dr Dominik Nischwitz, Dr Alexander Neubauer,  
Sabine Hutfilz, ZÄ Clara Esquinazi & ZA Paul Kilanowski

## case report

- Individual CAD/CAM abutments on ceramic implants 16  
Dr Frederic Hermann
- Aesthetic restoration in the incisal region 24  
Dr Michael Gahlert
- Immediate placement in the maxillary aesthetic zone 26  
Dr Saurabh Gupta & Dr Sammy Numbissi

## industry

- Change is mandatory for extraordinary results 30
- Ceramic implants in anterior dental restoration 32  
Dr Franz-Jochen Mellinghoff, M.Sc., PhD

## interview

- Clear trend towards metal-free reconstructions 40
- A shift to “well-care” 44

## events

- “The future of implantology—ceramics and biology” in Hamburg 46


## news

- manufacturer news 36
- news 49

## about the publisher

- imprint 50





“For me, biological dentistry and the use of ceramic implants are important milestones in dentistry.”

Dr. Alexander Neubauer, Tittling

“The opportunities for a dentist to make a positive contribution to patient health in this field, are truly enormous. In addition to the courses themselves, work shadowing Dr. Volz and his live procedures was always a great experience and proved really impressive. The idea of the concept being implemented in their own dental practices was very popular with patients right from the start. Courses in the areas of stress management, practice management and nutrition also contributed to holistic training and personal development that I wouldn't want to miss out on”.

**SDS** SWISS DENTAL  
SOLUTIONS

SDS Swiss Dental Solutions AG  
Konstanzerstrasse 11 · CH-8280 Kreuzlingen  
[info@swissdentalsolutions.de](mailto:info@swissdentalsolutions.de)

[swissdentalsolutions.com](https://www.swissdentalsolutions.com)

# From peri-implantitis to implant disease

## Will terminology and definitions change?

Dr Franz-Jochen Mellinghoff, M.Sc., PhD, Germany

**Current demographic prognoses show** that the proportion of elderly (population of 60 and above) will increase strongly in all developed and underdeveloped countries worldwide by 2050 (Fig. 1). This naturally results in an increasing stress on the global health system. One of the stressors that dentists can focus on is dental health, specifically regarding implants (Table 1).

Millions of dental implants made from titanium are inserted annually worldwide. They are especially used for the elderly, in order to rebuild the functional and aesthetic purposes of teeth after partial or total loss. Implant therapy has therefore developed into a procedure which allows very demanding dentures in faster and cheaper ways.

### Implantological developments

With the development of titanium implants from 1965 to 1990 there was a wave of excitement and hope among

both dental practitioners and patients in need. This technology was new, fascinating, and incredibly profitable. Unfortunately, in the excitement to apply this new technology the much needed research on the still unknown side effects began to diminish and the focus quickly turned to treatment diversification and profit.

Fast forward 52 years to present day and we now see that implants can lead to some form of bodily reaction presented as infection. These infections are described as mucositis and peri-implantitis. It can be observed that the implant disease starts with mucositis and progresses towards a status of peri-implantitis and can even progress as far as to result in complete implant loss.

Recently it has been shown, that these problems of inflammation increase especially with titanium implants that have been inserted over a longer period of time.<sup>1</sup> The majority of respondent US implantologists reported that

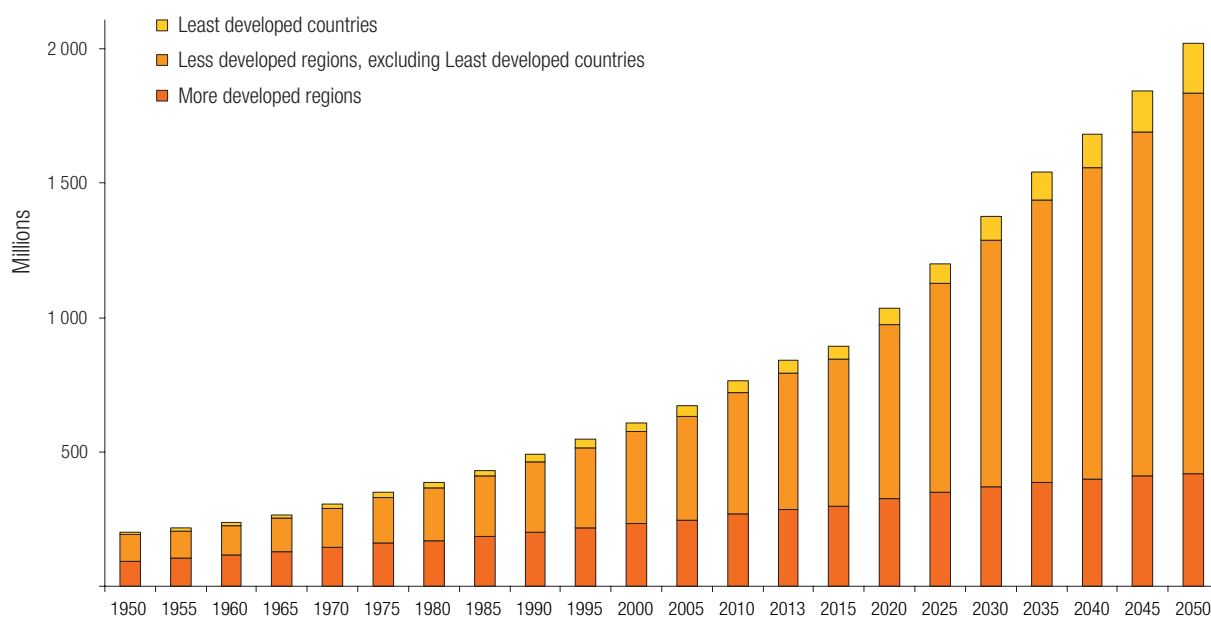


Fig. 1: Population aged 60 or above by development region. (Source: United Nations: World Population Aging 2013)



**Total solution for  
Function and Esthetics.**



[www.zibone.com](http://www.zibone.com)



2013	Inserted implants	Inhabitants	Inserted implants/ population (%)
Brazil	2,552,822	201,009,622	1.27
USA	1,805,011	316,668,567	0.57
Italy	959,124	61,482,297	1.56
Germany	795,243	81,147,265	0.98
South Korea	773,492	48,955,203	1.58
Spain	630,028	47,370,542	1.33
Japan	496,287	127,253,075	0.39
France	389,115	65,951,611	0.59
Russia	285,001	142,500,482	0.20
China	269,917	1,349,585,838	0.02
Switzerland	231,311	22,457,336	1.03
Canada	203,952	34,568,211	0.59
the Netherlands	142,843	16,805,037	0.85
UK	133,131	63,395,574	0.21
Australia	89,050	22,262,501	0.40
Austria	86,327	8,221,646	1.05
Portugal	77,755	10,799,270	0.72
Sweden	67,484	9,119,423	0.74
<b>Total:</b>	<b>9,987,893</b>		

**Table 1:** Overview of inserted implants by nation. (Source: Süddeutsche Zeitung [Uhlmann 2016], Press office DGI, KZBV, dental industry)

the prevalence of peri-implant mucositis and peri-implantitis in their practices is as high as 25 per cent. They estimated that there is an even higher proportion within the general US population.

Regarding this study and the fact that there is no proven therapy for this detrimental process, when consulting the published success rates it becomes obvious that more often than would be expected it results in implant loss. According to relevant literature, we can take 10 per cent as a minimum value for implant losses over the years.<sup>2-7</sup>

Even though aetiology is multifactorial and could not be clarified acceptably, there is a lot of evidence point-

ing towards titanium intolerance playing a decisive role in patient condition.<sup>8</sup> As studies were able to show, zirconium dioxide reduces that risk because ceramic, unlike titanium particles, do not provoke significant secretion of messenger substances for osteolytic processes.<sup>9</sup>

## Could ceramic implants be the (new) “next best thing”?

After a rough beginning, with frequent material breakages and very limited numbers of suppliers, ceramic implants are becoming increasingly more present in the field of dental solutions. More and more, informed consumers are demanding treatment options which are holistic and thus considering the body as a whole. To date, there is very little data of known implant disease regarding ceramic implants—not a bad start but will this data change? And if so, when, how, and by how much?

The now realised success with two-piece and specifically the new bone-level ceramic implants will lead to much greater use of ceramic implants, as a wide range of indications can be covered, that were until now reserved to titanium implants.

## Conclusion

In summary there could be a change of focus turning from peri-implant disease to implant disease. Bringing more focus to the implant disease in general medicine will give us a chance to investigate this phenomenon more seriously. This is a task for all participants in the field of implantology because knowledge about implant disease could lead to widespread uncertainty in our patients

and we need to be well informed in order to properly advise them.

## contact

### Dr Franz-Jochen Mellinghoff

**M.Sc., PhD**

Pfauengasse 14

89073 Ulm, Germany

Tel.: +49 731 62158


jochen.mellinghoff@dr-mellinghoff.de

www.dr-mellinghoff.de

Literature



Author details





ZIRCONIA IMPLANTS

# Be Different Think Zirconia



**TAVDental**

PRECISION. PASSION. PARTNERSHIP

[www.tavdental.com](http://www.tavdental.com) | [info@tavdental.com](mailto:info@tavdental.com)

# Analogous therapy for guided regeneration of lamellar bone tissue

Dr Karl Ulrich Volz, Prof. Dr Dr Ralf Smeets, Dr Martin Chares, Dr Stefan König MSc., Dr Dominik Nischwitz, Dr Alexander Neubauer, Sabine Hutfilz, ZÄ Clara Esquinazi & ZA Paul Kilanowski, Germany & Switzerland

**Regarding bone formation**, the regeneration of lost bone substance follows indisputable biological laws. The creation of cavities through so-called space makers in combination with the building of a blood clot within, has been a well-known procedure for guided bone regeneration for a long time. Due to growth factors in platelet-derived alphagranula there is a fast incrementation of blood vessels in the blood clot, followed by a fast bone regeneration through callus formation.<sup>1-3</sup> Herewith, the osseoinductive characteristics of the periosteum or the Schneiderian membrane can have a positive impact in addition. This form of bone formation leads to a histologically highly vascularised Havers' bone morphology in the long term and is functionally superior to regenerated bone, formed by bone substitution materials, especially regarding the response behaviour by induced pressure.

The new SDS sinus implant of the series "bone growing implants" supports the so-called form of callus bone formation<sup>4,5</sup> with its specific macro geometry based on the tent pole/sunshade principle, creating a stable and voluminous cavity (bio container) kept open over the necessary time scale, so that by waiving bone substitution material new biological bone of highest quality can be generated.

## Objective

The aim of our work has been to develop a reliable surgical procedure without secondary materials for augmentation, which creates suitable bone in the sinus maxillaris evaluated quantitatively and qualitatively in which dental implants can be anchored with high predictability. Besides a significant reduction of surgical risk as well as postoperative complications, and thus surgical stress for the patient, a substantial cost saving can be achieved for the patient.

## Material and method

Modified zirconium dioxide implants of SDS Swiss Dental Solutions AG, Switzerland, have been used. On the apical end



they show a disc-like and preferably wide plateau for extensive and risk limited support concerning perforations of the Schneiderian membrane. Simultaneously, there should be created a peri-implant cavity kept open over the required time for creating a bioactive container. In it an entirely autologous and blood clot initiated bone formation should take place, which should

lead to Havers' bone morphology in the long term (Fig. 1).

## Biological Principles

### Systemic conditions

General ability of the organism to form new bone must be enhanced prior implant insertion. For this purpose, patients were instructed to set their LDL (Low Density Lipoprotein) below 1,2g/l and their vitamin D3 level (25-OH-Cholecalciferol) at greater than 70ng/ml by following a certain diet and by the intake of a specific vitamin and mineral nutrients mix (BASIC IMMUNE, SWISS BIOHEALTH AG). According to the study of Choukroun et al. (2014), the risk of infection reduces and the bone formation accelerates.<sup>6</sup>

### Local conditions 1

Improvement of the extracellular matrix by creating a stable cavity formed by the osseous floor of the sinus and the Schneiderian membrane. Palma et al. (2006) showed that new bone is formed in contact to the Schneiderian membrane on a regular basis, also in mere blood clot areas proving the osteoinductive quality of the maxillary sinus membrane.<sup>7</sup>

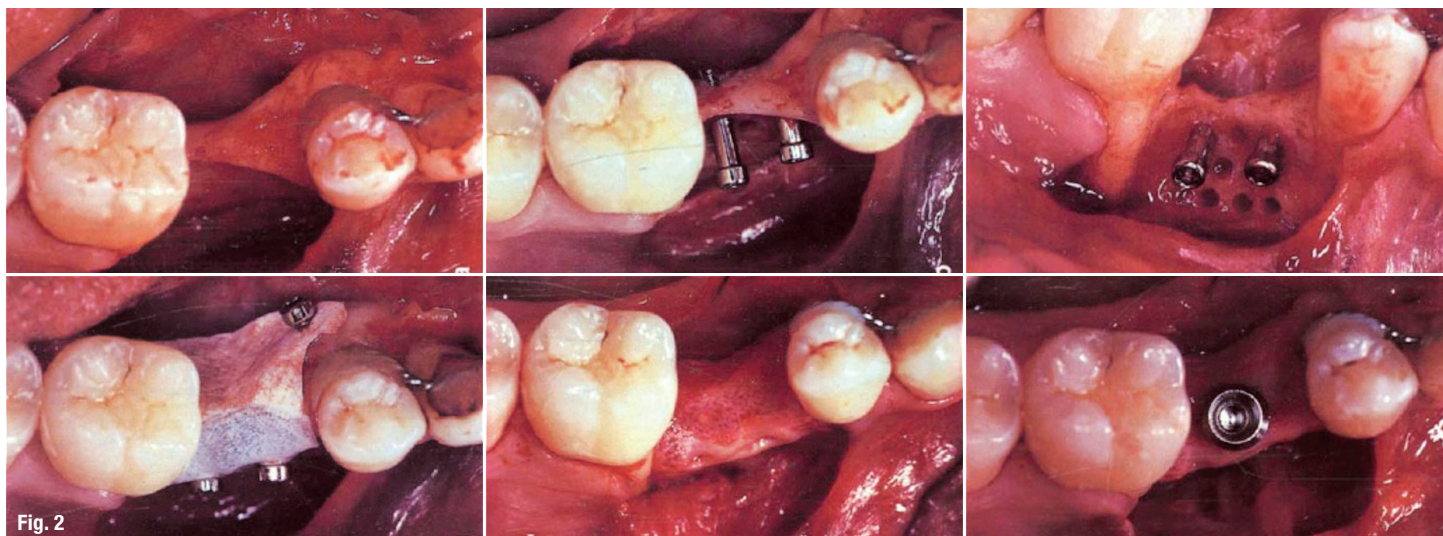
### Local conditions 2

Continuity of the circulation in the newly formed bone. Mammoto et al. (2009) postulate that the long-term maintenance of regenerated bone depends in particular on the maintenance of the bone's blood circulation.<sup>8</sup>



**Fig. 1:** The two-piece SDS ceramic implant shows a disc-like bulge with soft roundings on the apical end, not only widely supporting the membrane at reduced risk, but also creating a cavity to the thread.





**Fig. 2:** The tent pole/sunshade principle has been demonstrated impressively in the publication of Hämmerle et al. (2000).<sup>9</sup>

The avoidance of secondary materials for bone replacement increases the amount and extent of a highly vascularised Havers' bone morphology, which develops from an initial vascularisation within an autologous blood clot with subsequent ingrowth of cortical bone transforming to lamellar bone.<sup>3</sup>

#### Tent pole/sunshade principle

In 1998, Hämmerle et al. (2000) already have shown that high volumina of new bone could be created by the so-called Memfix® system, without the need of bone block or granular bone graft material.<sup>9</sup> The periosteum has been kept at a distance through a tent pole (Memfix® screw). In addition, GORE-TEX® membranes have been placed and fixed on one or more tent poles to protect and seal the cavity (Fig. 2).

The significance of the periosteum for bone regeneration is now undisputed. Srouji et al. (2009) noted, that the Schneiderian membrane is periosteum, which produces all necessary humoral and cellular factors needed for bone regeneration, like bone morphogenetic protein 2, only with the presence of a blood clot and without the existence of calcified structures.<sup>10</sup>

Further studies show, that the periosteum is an outstanding source for bone forming progenitor cells. Forget et al. (2011) point out the periosteum's ability of local angiogenesis.<sup>11</sup> Marolt et al. (2015) show the existence of bone forming stem cells in the periosteum,<sup>12</sup> You-Kyong et al. (2016) conclude:<sup>13</sup> "Thus, periosteum-derived cells can be expected to be a good source for bone regeneration."

We also know today that no artificial membranes are necessary. The sealed and cavity stable cover of the periosteum or Schneiderian membrane is sufficient to effec-

tively protect the cavity. This waiver then again lowers the risk of infection or a dehiscence and reduces the cost of intervention. The additional insertion of PRF membranes stabilises the blood clot in the cavity and supports the bone and tissue regeneration (Fig. 3).<sup>14-16</sup>

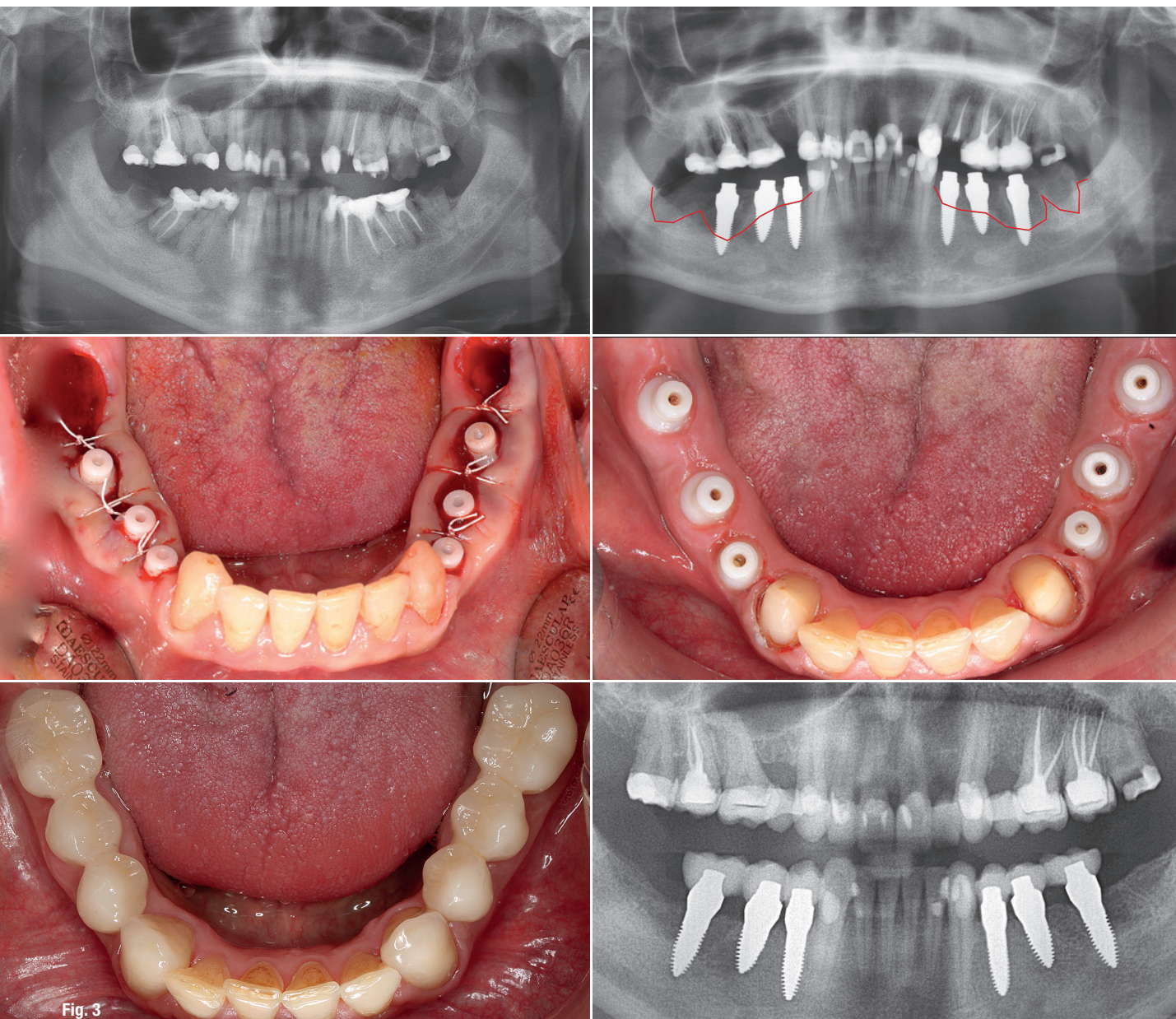
According to the idea of Choukroun and Simonpieri, which is a further development of the root disc protocol of Randelzhofer et al. (2016),<sup>17</sup> we fixed zirconia discs on top of SDS ceramic implants when facing extended defects. Complete bone regeneration in the defect could be achieved with the use of A-PRF (Fig. 4). Asymmetric bulges on ceramic implants (SDS balcony implant) also lead to a full bone regeneration by sealing the adjacent socket and due to the sunshade effect (Fig. 5).

#### Literature research

Various groups have done intensive research on generating new bone in the maxillary sinus without bone substitution material:

1. Palma et al. (2006) have shown, that new bone is regularly formed by being in contact with the Schneiderian membrane in mere blood clot areas and thus showing the osteoinductive potential of the membrane ("New bone is frequently deposited in contact with the Schneiderian membrane in coagulum-alone sites, indicating the osteoinductive potential of the membrane.").<sup>7</sup>
2. Cricchio et al. (2009) have installed absorbable space makers and could show, that, almost exclusively in the combination of simultaneous implant placement, it was possible to generate bone along the implant surface ("Histologically there were only minor or no signs of bone formation in the sites with a space-making device only. Sites with simultaneous implant placement showed bone formation along the implant surface.").<sup>18</sup>





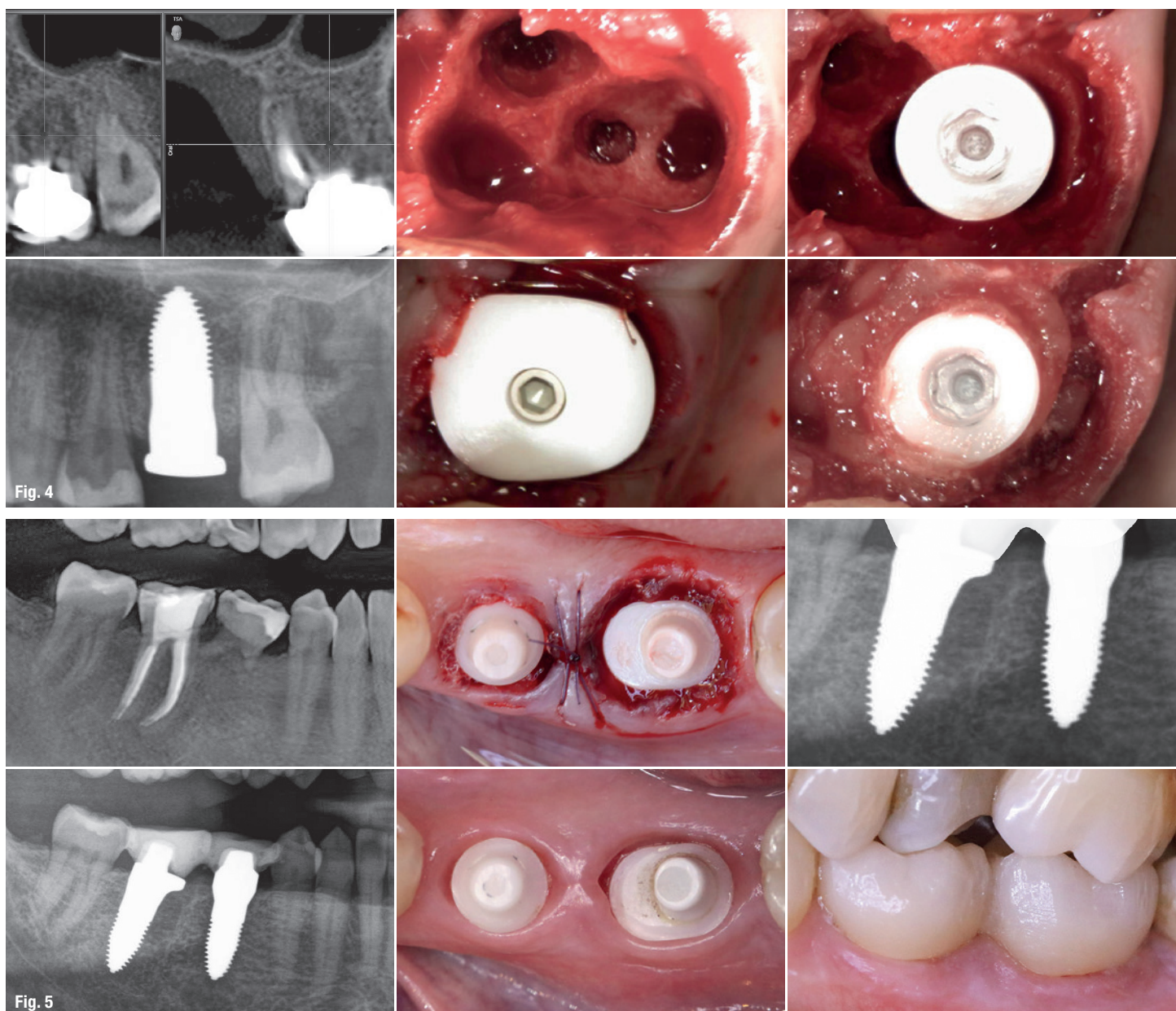
**Fig. 3:** During a surgery with immediate implant placement, the implants were placed at the desired level of the regenerated bone. The unharmed periosteum as well as the attached gingiva were fixed over the tulip formed widening (“sunshade principle”) of the SDS ceramic implant, which results in a stable cavity. The panoramic X-ray shows the final restoration with e.max crowns after only 2.5 months postoperatively with complete bone regeneration at the desired level.

3. Junger et al. (2015) have found out that “bone formation after sinus membrane elevation with or without additional bone grafts starts at the sinus floor and sprouts into the elevated space along the implant surface”.<sup>19</sup>
4. Cricchio et al. (2011) have proven that “when the sinus membrane was elevated, bone formation was a constant finding”.<sup>20</sup> Therefore, “an ideal space-making device should be stable and elevate the membrane to ensure a maintained connection between the membrane and the secluded space”.
5. Sohn et al. (2008) have shown the capacity of new bone formation in the maxillary sinus after elevating the Schneiderian membrane and simultaneous insertion of

implants into the resulting cavity without using any additional bone substitute.<sup>21</sup> “New bone formation without additional bone graft in the maxillary sinuses revealed from the clinical, radiographic, and histologic results...”

Summarising the aforementioned studies, it can be concluded that an optimal one stage result can be achieved by a bone substitute free insertion of an implant, whose design is able to lift the Schneiderian membrane without perforating it, as well as to create a voluminous and stable cavity. Additionally, this cavity must be kept stable and sealed against the oral cavity. This led to the development of the sinus implant.





**Fig. 4:** After an internal sinus lift, the implant was stabilised only in the compacta of the maxillary sinus floor. The cavity was filled with A-PRF and the socket was sealed with a disc abutment in the sense of a sunshade. The defect has fully recovered after four months. **Fig. 5:** Implant placed in the distal socket of region #46, covering the medial socket after being filled with A-PRF. Complete regeneration of the hard- and soft-tissue.

## Surgical protocol

Preparation of the immune system by adjuvant systemic therapy (adjusting the LDL and D3 levels, see above) and highly dosed vitamin C infusion as well as single shots of 600mg Sobelin and 8mg Dexametasone i.v. on three consecutive days (-1, day of surgery, +1). The surgery can be performed in local anaesthesia only.

- Incision on the maxillary crest with gingival margin cut at the neighbouring teeth to avoid a vertical incision.
- Avoidance of incision of the periosteum with the brushing technique by Choukroun et al. (2016) to achieve

tension and movement free coverage in combination with apical mattress sutures.<sup>22</sup>

- Thinning out the vestibular bone in the area of the window with the help of the safescraper (Safescraper® TWIST, straight) and simultaneous gain of cortical chips.
- Usage of piezo surgery (Piezotome Solo F 57 500, Kit "Extern Sinuslift" F 87 319 Bone Surgery BS1) to remove the bone window without perforating the Schneiderian membrane.
- Elevation of the Schneiderian membrane far to the medial, dorsal and palatal side. This ensures the blood supply for the cavity<sup>23,24</sup> and secures the sinus implant,



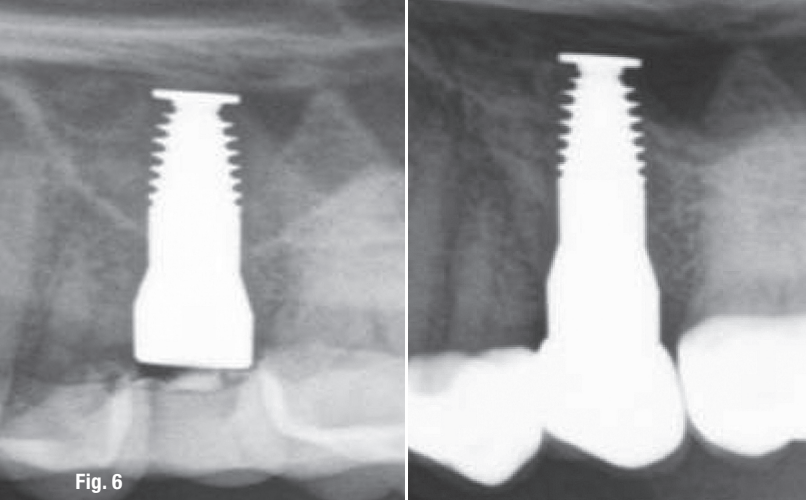


Fig. 6

**Fig. 6:** Result after six months postoperatively. One can observe, that there could be gained enough satisfactory bone quantitatively and qualitatively.

because there shall not be any tension on the membrane with expulsive forces on the sinus implant.

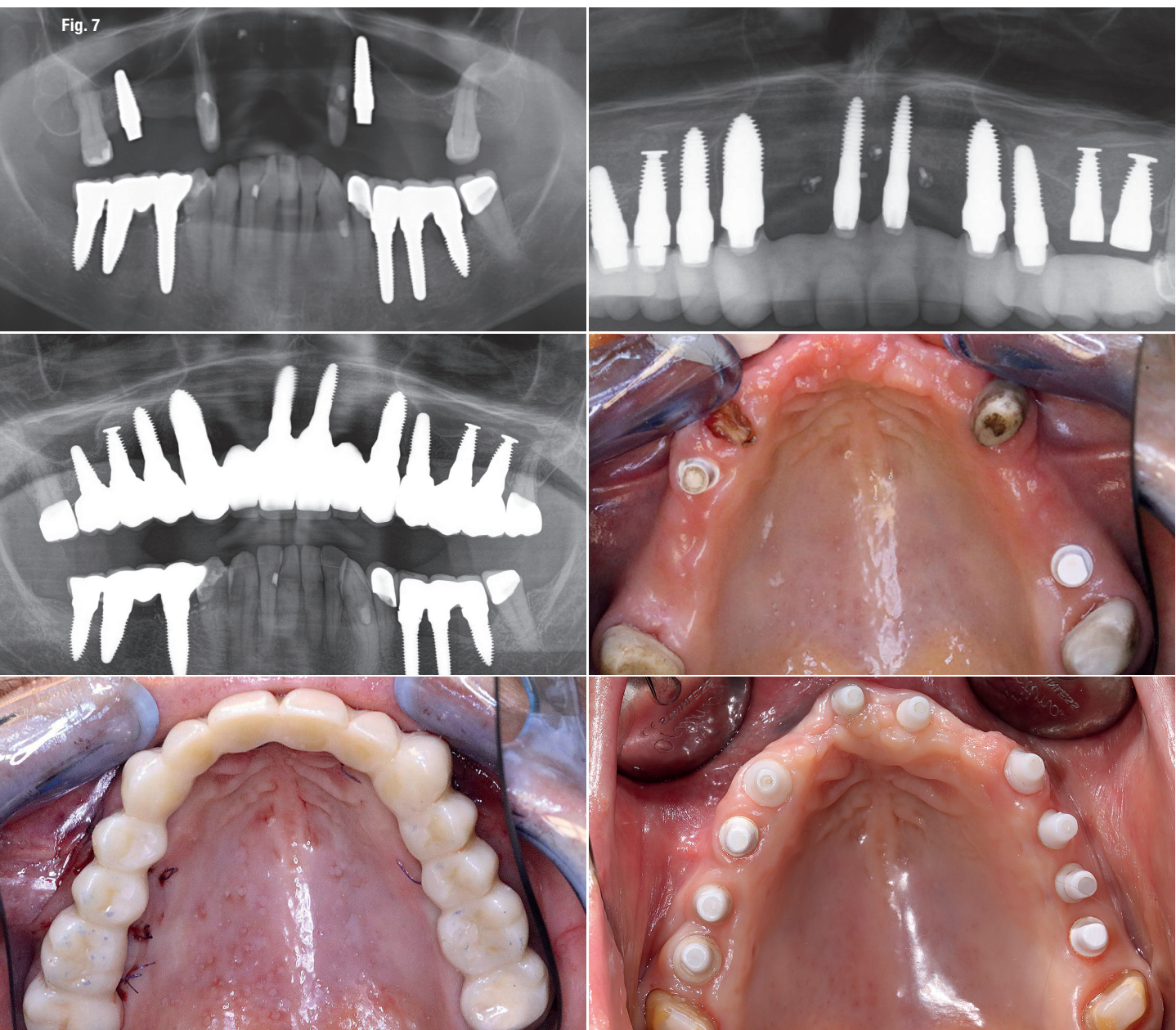
- Reinforcement of the membrane with one layer of A-PRF, insertion of the sinus implant and placement of the bony lid of the vestibular window on top of the disc of the sinus implant to enlarge the "shadow effect". Filling the cavity with more A-PRF membranes and cortical chips from the Safescraper.

- Closure of the window with cortical chips, covering with one or two A-PRF membranes and saliva proof and tension free wound closure. This is achieved by a two-layer suturing technique (apical mattress sutures and single button or continuous sutures) with a monofil, atraumatic suture material, preferably PGC25 (Atramat®). PGC25 shows the lowest bacterial adherence rate and therefore significantly minimises the incidence of stitch canal infection, which is a possible secondary complication.<sup>25,26</sup>

## Results

The slight radiopacity due to the cortical chips and the A-PRF show, that the cavity space was attained and the bony lid placed on top of the disc of the sinus implant (Fig. 6). Figure 7 shows an extensive treatment using SDS ceramic implants and three sinus implants on both sides. The results of the bone formation after four and eight months show a perfect situation regarding hard- and soft-tissue around the implant (Fig. 8).

**Fig. 7:** Insufficiently pre-treated maxillary situs, after inserting eight more implants in the maxillary, sinus lift on both sides, bone formation in the front.





**Fig. 8:** Significant bone formation already after four months and continuous improvement after another four months.

## Conclusion

The external and internal maxillary floor elevation using secondary materials for augmentation is a standard surgical procedure in oral implantology. However, complications such as infections or dehiscences up to total loss are still a regular problem. Unfortunately, in most cases “restitutio ad integrum” cannot be expected. The maxillary sinus floor mucosa as well as the soft tissue are mostly permanently compromised. On the one hand, the presented therapy concept allows for a minimally invasive and atraumatic surgical procedure, which only uses autologous materials.

On the other hand, only highly biologically compatible, metal-free implant materials are inserted. The complication-free processes and the outstanding results up to date in regard to the clinical, radiological as well as the bone and soft tissue situation are very positive. This presents a promising alternative for the practitioner. In case of complication, the worst that could happen in this treatment concept, is falling back to the original condition.

It is now necessary to confirm these results sustainably in regard to patient quantity and observation period within long-term studies.

Prof. Dr Dr Ralf Smeets  
Author details



Dr Martin Chares  
Author details



Dr Stefan König  
Author details



Dr Dominik Nischwitz  
Author details



Dr Alexander Neubauer  
Author details



Sabine Hutfilz  
Author details



## contact

### Dr Karl Ulrich Volz

Biological Medical & Dental Clinic  
SWISS BIOHEALTH AG  
Brückenstr. 15  
8280 Kreuzlingen, Switzerland  
dental@swiss-biohealth.com  
www.swiss-biohealth.com

Author details

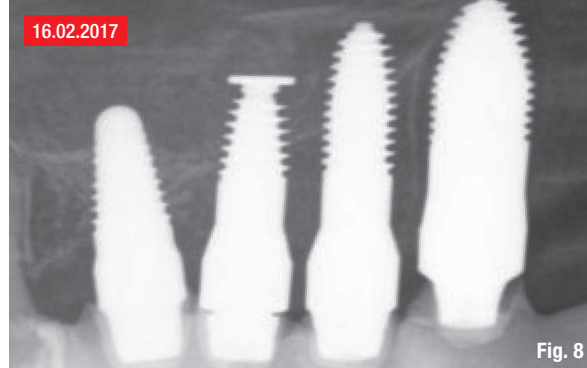
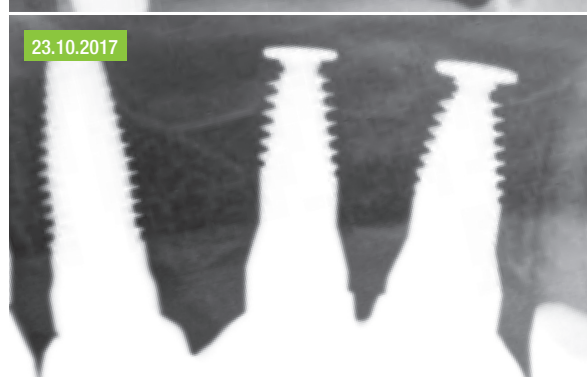
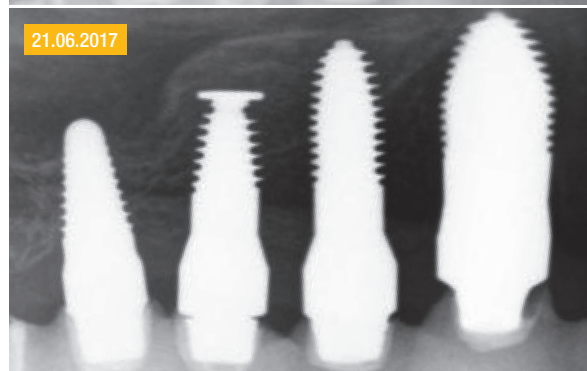Fig. 8



# Individual CAD/CAM abutments on ceramic implants

Dr Frederic Hermann, M.Sc., Switzerland

**Full-ceramic systems** have been successfully established in the field of dental technology as well as in oral surgery.<sup>1</sup> The necessity of being able to offer patients metal-free restorations has continuously increased in recent years.<sup>2</sup> Owing to a genuine two-piece design, the newer generation of ceramic implants allows for successful restoration concepts similar to titanium implants. The reconstruction of an edentulous space in the upper jaw with simultaneous, transcrestal sinus floor elevation by using three CERALOG® implants will be described in the following case report.

## Case presentation

In January 2015, the 42-year-old patient desired a holistic and metal-free reconstruction of the teeth, which were either missing or in need of restoration (Fig. 1). The bridge in region #15–17 had been removed by his family dentist a few years ago and the gap situation had not been prosthetically restored since (Fig. 2). The patient had already gathered restoration information and thus desired his missing teeth to be replaced with ceramic implants. The assessment of the radiological findings indicated an adequate bone width with simultaneously reduced bone height, which was caused by alveolar bone resorption and maxillary sinus pneumatization. A wide zone of attached mucosa existed in the anticipated area of implant emergence. The case-related risk classification by means of SAC criteria revealed an A classification (A=advanced; Table 1).

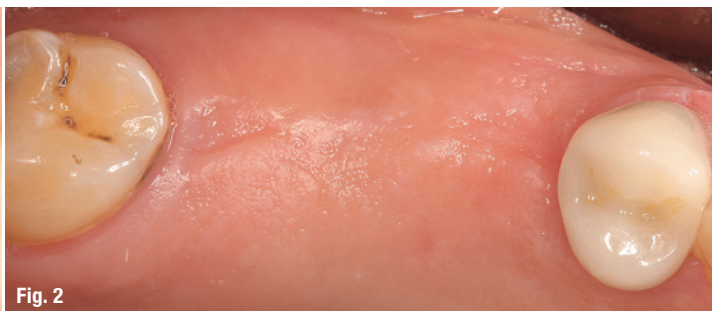
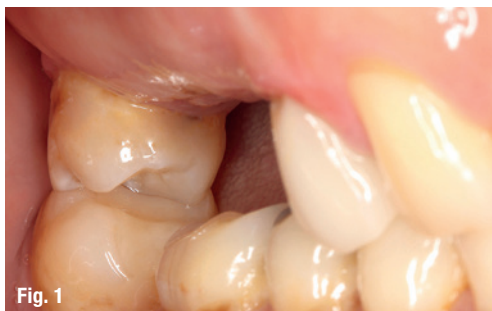In a preoperation consultation, the patient was informed in detail about the intended procedure and the possible risks. The special features of ceramic implants were par-

ticularly addressed. On the one hand, the present research situation, the role as a “maverick technology” and the alternative to titanium implants were addressed, while the positive biological, immunological and tissue-compatible aspects were discussed on the other hand.

Prior to the surgical procedure, the areas in need of restoration in the second and third quadrants were restored with full-ceramic bridge reconstructions as well as with a CAD/CAM-manufactured lithium disilicate crown in region #14. The prosthetically oriented implant positioning was digitally planned to achieve the highest clinically possible predictability of treatment success. Thus the three digitally designed crowns were overlaid with the DVT data according to the intraoral scanning method (Fig. 3). The positions, axial alignments and the lengths of the three implants were determined with the aid of planning software (Fig. 4). Since there is still no guided solution for the implant system utilised here, an orientation template was made in the laboratory on the basis of the accumulated planning data reproducing the anatomical marginal boundary of the teeth to be replaced as well as the alignments. The template could be exactly supported by the adjacent teeth (Fig. 5).

## Implantation

The crestal incision was made after performing successful infiltration anaesthesia with preceding surface anaesthesia. It was carried out in a slightly palatally oriented manner and continued paramarginally vestibular around tooth #18. No distal vertical relief incision was made, in order not to reduce the blood supply in the flaps. After the

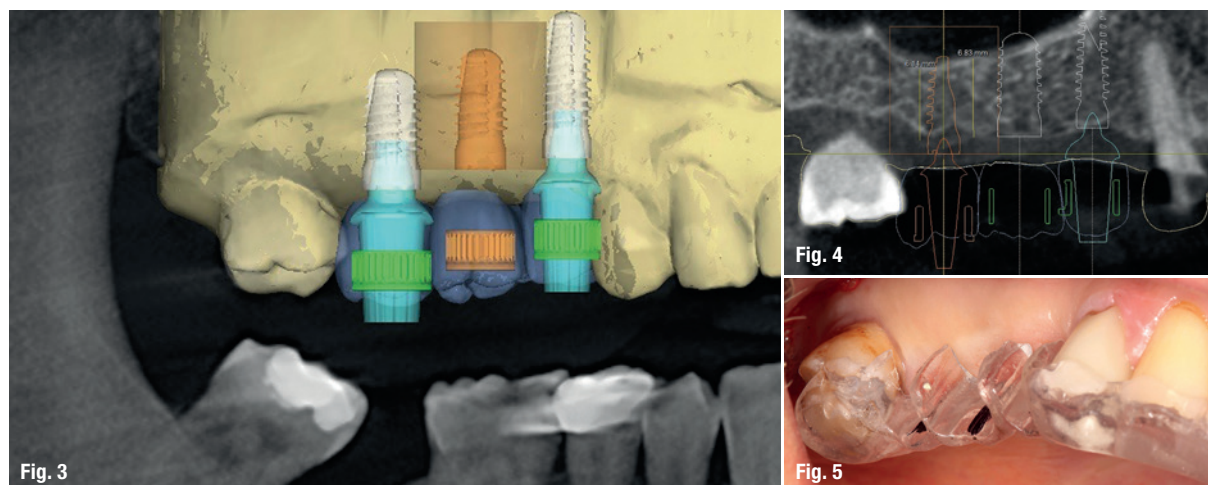


Figs. 1 & 2: Initial intraoral situation.



	low risk	moderate risk	high risk
1. health status	good	treated	bad
2. smoking (p/day)	0	0–10	> 10
3. oral hygiene/compliance	good	moderate	bad
4. periodontal status	good	moderate	bad
5. aesthetic demands	low	moderate	high
6. level of the smile line	low	moderate	high
7. gingival biotype	thick	moderate	thin
8. infection	no	chronical	acute
9. distance bone to contact point	< 5 mm	5.5–6.5 mm	> 7 mm
10. restorative status of the neighbour teeth	no		restored
11. width of the gap	single > 7 mm	single < 7 mm	> 2 teeth
12. soft tissue condition	intact	reduced	defect
13. bone volume	no defect	horizontal defect	vertical defect
14. time of surgery	late	early	immediate
15. loading time after surgery	> 2 months post-op	1 weeks – 2 months	immediate

**Table 1:** Assessment of medical findings and risk classification by means of SAC criteria.



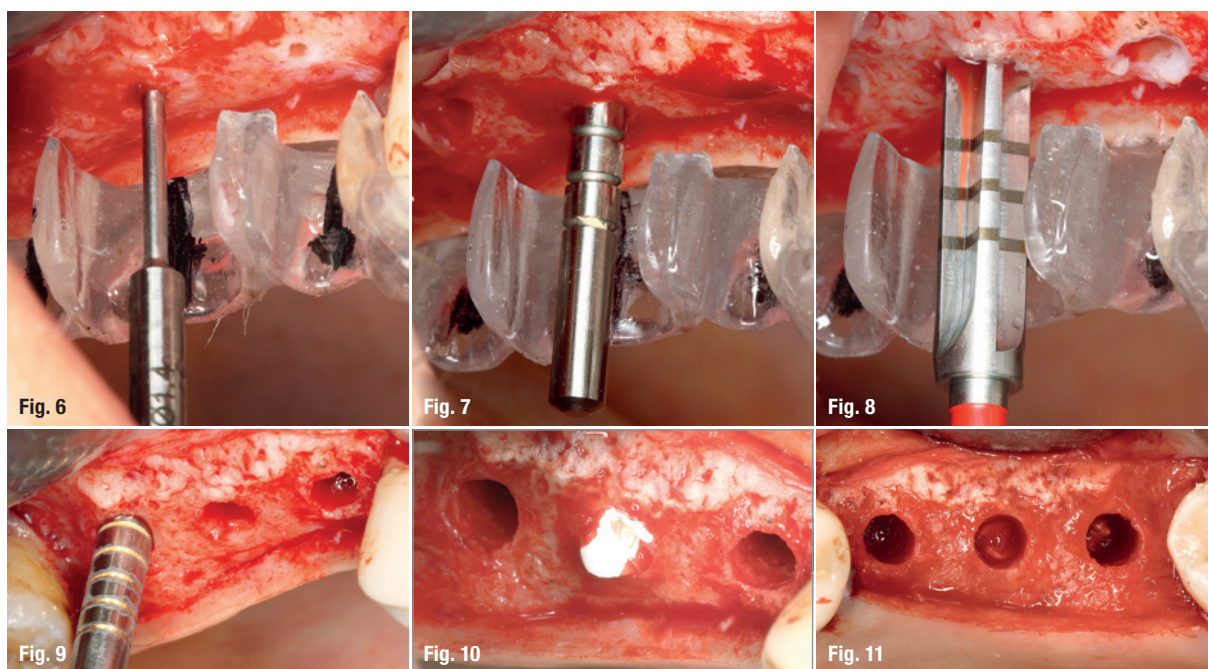
**Fig. 3:** 3-D planning: overlay of datasets. **Fig. 4:** Planning visualisation. **Fig. 5:** Try-in of the drilling template.

preparation of the mucoperiosteal flap, the position of the implant was marked on the bone using the triangular drill and orientation template.

In the next step the pilot drill holes were created reaching slightly beneath the maxillary sinus floor, as in the following step the sinus floor was to be elevated using the osteotome

technique. The axes of the drilled hole were examined with the aid of directional indicators and the implant site was expanded according to the surgical protocol (Figs. 6–8).

The indirect technique for augmenting the sinus floor through the drill holes was for the first time described by Tatum in 1986 and modified by Summers in 1998 on



**Fig. 6:** Definition of the implant positions. **Fig. 7:** Paralleling pin. **Fig. 8:** Red extension drill. **Fig. 9:** Minimally invasive osteotome-aided sinus lift in region #17. **Figs. 10 & 11:** Application of collagen fleece beneath the Schneiderian membrane.

the basis of the osteotome technique.<sup>3-5</sup> A systematic review of specialised literature revealed that this approach is predictable, and has low incidence for intraoperative as well as postoperative complications.<sup>6</sup> The fracture of the sinus floor beneath the drill holes was initiated with an osteotome (Stoma) according to the implant diameter (Fig. 9). With the aid of the Piezon technology and specifically angled miniature sinus curettes, the Schneiderian membrane stayed always in touch with the bone and was carefully lifted under visual control (surgical microscope). Collagen fleece (PARASORB, RESORBA) was inserted through the drill holes in region #16 and 17 and carefully applied over the implant site in order to prevent a perforation of the Schneiderian membrane (Figs. 10 & 11).

Thread cutting was performed to avoid overheating the bone while inserting the zirconium dioxide implants, which have lower thermal conductivity than titanium implants (Fig. 12). The implants (CERALOG® Hexalobe, CAMLOG) of 8mm in length were inserted manually at a controlled maximum torque of 35Ncm and a maximum insertion speed of 15/min (Fig. 13). The design of the connection was optimally adapted to zirconium dioxide. The power transmission occurred radially with the insertion device. A predetermined breaking point in the device shields against an excessively high-torque value and therefore against excessive pressure which could initiate fractures in the implant or necrosis in the bone (Table 2).

The design of the implants utilised here was beneficial to the existing low bone height, thereby preventing the possibility of slipping into the maxillary sinus. Zirconium

dioxide implants are manufactured in a ceramic injection-moulding (CIM) process obtaining a dual surface. The surface texture in the neck region is less coarse than in the enossal region favouring soft tissue apposition, whereas the surface in the enossal region is optimised for osseointegration. The implants were inserted about 0.5mm supracrestally and primary stability was achieved at 25Ncm (Fig. 14). After the insertion of the implants, the collagen fleece was situated apically like a screen above the implants in region #16 and 17, which were protruding two to three millimetres into the sinus floor. A blood clot formed in the created cavity favouring regeneration into stable bone through the formation of growth factors during implant healing.<sup>7</sup> The intraosseous, periodontal bone defect in region #18 was filled with a pure phase beta-tricalcium phosphate (Fig. 15).

Mixed with patient blood taken from the surgical site the porous synthetic granulation can be easily applied. After about six to nine months the material regenerates into stable cortical bone. After sealing the implants with the cover cap made of polyether ether ketone (PEEK), tension-free wound closure was performed with two mattress sutures and multiple simple interrupted sutures (Fig. 16). Further, a radiographic control image was taken (Fig. 17).<sup>8</sup> The patient left the practice with a renewed reference regarding postoperation behaviour focusing on care and non-strain.

Suture removal was performed during the two-week check-up showing well and irritation-free wound healing. The patient appeared six months later for implant exposure. The implants in region #15 and 16 were exposed




# AWI

*AWI Circonia Implants: now available in gingiva color.  
For better results in esthetic relevant areas.*

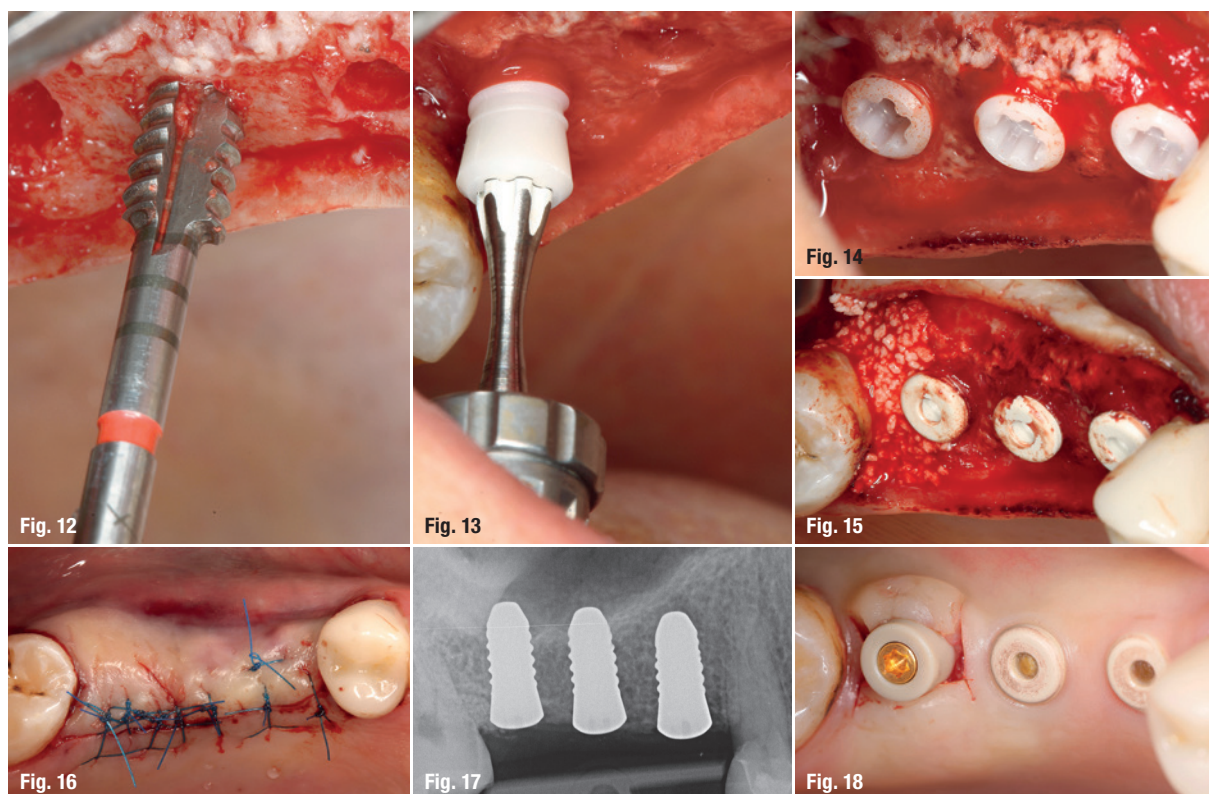
*G-Line*



[www.WITAR.de](http://www.WITAR.de)







**Fig. 12:** Thread cutting. **Fig. 13:** Implant insertion in region #17. **Fig. 14:** Implants inserted at 0.5 to 1.0 mm supracrestally. **Fig. 15:** Guided bone regeneration (GBR) of intraosseous periodontal bone defect. **Fig. 16:** Tension-free wound closure. **Fig. 17:** Postoperative radiographic control image. **Fig. 18:** Six-months post-op exposure surgery.

with a stab incision, the cover cap was removed and the PEEK gingiva former was screwed on with the aid of a holistic screw for shaping the gingiva. The soft tissue around the implant in region #17 was pre-prosthetically thickened by preparing a mucosa flap and shifting it into vestibular direction. This shaping with a 2.5 mm high gingiva former was also performed without any additional suture being necessary (Fig. 18).

## Definitive restoration

The implants and the jaw situation were moulded for the production of individual definitive full-zirconium dioxide abutments. For taking the impressions according to the open tray technique the gingiva formers were screwed off and the PEEK impression posts were inserted. Some practice is necessary to control the exact fit during the subsequent radiographic control image, since the material is only marginally radiopaque (Figs. 19 & 20).

The master model with a removable gingival mask was produced in the laboratory. Scan posts were screwed on and the morphology of the implant as well as the gingiva was digitally recorded. The data compiled from the wax-up was merged with the model data, and three individual abutments were designed in consideration of material thicknesses and the anatomical coronal-emergence profiles.

Six days after order placing, the laboratory received the CAD/CAM-manufactured abutments. The design of the internal connection was adapted to zirconium dioxide and ensured an optimal distribution of the forces involved. Owing to the limitations of milling radii the full-zirconium dioxide abutments (DEDICAM®, CAMLOG) were made with platform switching. The abutments were screwed on in the laboratory and the subgingival parts were checked for hygienic capability (Fig. 21).

Another important step was the reliable prosthetic crown restoration. For this purpose, prototypes were made from polymethyl methacrylate by 3-D printing on the basis of already existing STL datasets. The occlusion, contact points, hygienic capability as well as shape and aesthetics can be checked intraorally during a prototype try-in with these cost-effective synthetic crowns. Owing to the integrated platform switching and the occlusal structure height, the coronal emergence profile in region #16 could not be optimally aesthetically solved (Figs. 22 & 23). As zirconium dioxide has a lower accumulation of plaque and the subsequent hybrid-abutment crown would be easy to clean in this area, this situation was assessed as clinically acceptable.<sup>9,10</sup> Owing to consistent prosthetic backward planning, the zirconium dioxide crowns—which are to be buccally veneered later—could be made with an integrated occlusal screw




# 4<sup>TH</sup> ANNUAL MEETING OF ISMI

22 & 23 June 2018

Hamburg, Germany—EMPIRE RIVERSIDE HOTEL

BOOK ONLINE /  
CONGRESS PROGRAMME



[www.ismi-meeting.com](http://www.ismi-meeting.com)



## Theme:

The future of implantology—ceramics and biology

## Organisation/Registration:

OEMUS MEDIA AG

Holbeinstraße 29 | 04229 Leipzig | Germany

Phone: +49 341 48474-308 | Fax: +49 341 48474-290

[event@oemus-media.de](mailto:event@oemus-media.de) | [www.oemus.com](http://www.oemus.com)



Fax Reply **+49 341 48474-290**

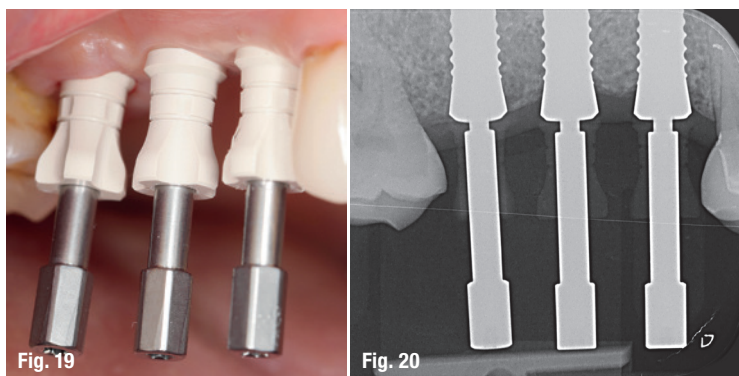
☐ I would like to receive further information on the 4<sup>TH</sup> ANNUAL MEETING OF ISMI.

\_\_\_\_\_  
Title, Surname, Name

\_\_\_\_\_  
E-mail address (for digital programme)

Stamp

CI 1/18



**Fig. 19:** Lateral view of impression posts. **Fig. 20:** Radiographic control image.

access channel. After crown finalisation, they were adhesively attached to the abutments in order to produce one-piece fully anatomical hybrid-abutment crowns. The hybrid-abutment crowns were inserted into the mouth with titanium screws at a torque of 25 Ncm after function and aesthetics had been controlled.

Cement residues have been repeatedly discussed in literature as being the cause of an emerging mucositis or peri-implantitis. This risk was eliminated with the screw-retained solution. The screw access channels were initially filled with sterile Teflon tape and then sealed with methacrylate-free composite (Fig. 24).

During follow-up appointments at one and six weeks after the insertion of the full-ceramic implant restoration the soft tissue proved to be stable and irritation-free. The osseointegrated ceramic implants and the osseously regenerated periodontal defect mesial of region #18 were apparent on the radiographic control image (Fig. 25). The patient was very satisfied with the holistic rehabilitation of his oral situation.

## Discussion

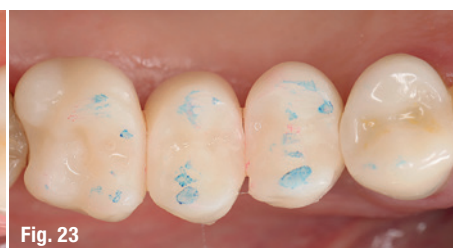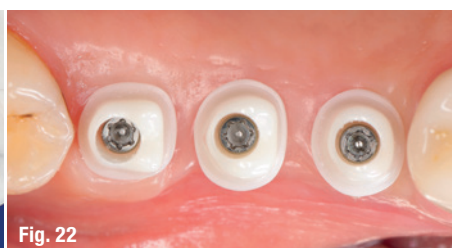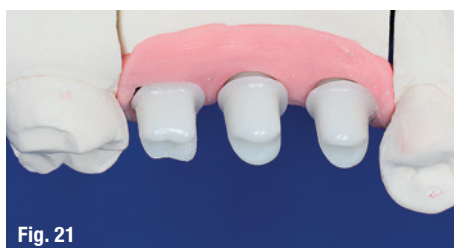The patient demand for ceramic implant restorations is undisputedly increasing.<sup>2</sup> The aesthetic and health-related needs of patients should be considered in the treatment concept. In doing so, clinically proven systems provide us with certainty. A dual surface roughness without mechanical finishing is created through the modern

manufacturing process known as CIM. Adapted to the soft-tissue cells, the neck region exhibits a roughness with an average roughness value of 0.5 micrometres and the enossal region exhibits a roughness of 1.6 micrometres. As a result, outstanding osseointegration properties can be attained.<sup>11,12</sup>

Abutments made of the high-performance polymer PEKK are offered as a standard for two-piece implants. In medical technology, the material is used in areas with high load levels. PEKK is biocompatible and has a great degree of strength. Because of the chemical composition and ductility these abutments cover the entire implant platform, including the circular slanting bevels. A uniform choice of materials is guaranteed with the option of individual, CAD/CAM-manufactured full-zirconium dioxide abutments. Owing to the milling geometry, the full-zirconium dioxide abutments can only be made with integrated platform switching. The choice of abutment used for the reconstruction should be defined during the implant positioning, as the abutments influence the vertical position of the ceramic implant.

When setting the PEKK abutment on the shoulder, the implant platform should be placed between 0.5 and 1.5 mm supracrestally. In case of thick gingiva (> 3 mm), supracrestal placement is possible with zirconium dioxide abutments. However, owing to platform switching a slightly subcrestal or epicrestal positioning is advantageous for the prosthetic emergence profile if adequate bone supply is available (Table 2). The connection is secured with the aid of a titanium screw or a holistic gold screw, which does not have any connection to the oral environment when embedded in the overall construction. Today, the genuine two-piece design of the implant system offers similar treatment procedures as with titanium implants.

For successful treatment therapy 3-D planning by means of DVT datasets has become established in the dental practice. The optimal prosthetically oriented position of implants can be determined through a template-guided or template-oriented surgery and the digitally designed reconstruction. After successful osseointegration, the intraoral structures can be scanned or conventionally moulded. With the aid of a laboratory scan and the open STL datasets the abutments can be designed and com-



**Fig. 21:** Abutments on the model. **Fig. 22:** Try-in of the abutments. **Fig. 23:** Occlusion control and adaptation of prototypes.

## Thermal conductivity

The insertion device for Hexalobe® implants is equipped with a predetermined breaking point, which:

- prevents excessive torque and excessive load,
- breaks with excessive load, and
- prevents damage on the implant.



## Primary stability/protocol

The drilling protocol depends on bone quality.

- CERALOG® has no self-tapping thread

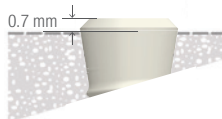
Pre-tapping a thread is strongly recommended in case of hard bone (D1/D2).

The following torques have to be noted:

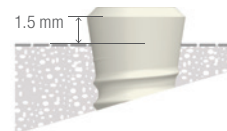
- maximum torque of 35 Ncm, and
- maximum speed of 15/min.

## Positioning

Individual DEDICAM® full-zirconium dioxide abutment: owing to the integrated platform switching, the implant should be positioned epicrestally.



The PEKK abutments completely contain the platform's circular bevel. The implant can be placed supracrestally between 1.5 and 0.5 mm.




The use of a profile drill is recommended in epicrestal placement.

- controlled expansion of the implant bed in the crestal region

## Prosthetic portfolio

Components for crown and bridge restoration:

- PEKK (straight and angled)
- DEDICAM® abutment



**Table 2:** Factors to be noted for the insertion of CERALOG® implants.

missioned via the DEDICAM® production service. The material-dependent exact milling data are only stored in the CAM production. After a controlled sintering process lasting over three days, a precise fit to the internal config-

uration of the implant is attained. Subsequently fully anatomical crowns or crown frameworks are produced in a dental laboratory or by means of a production service provider and individually veneered by dental technicians.

Currently the prosthetic portfolio for two-piece ceramic implants is still limited, thus the indications for restoration with fixed crowns or smaller bridge reconstructions are still limited. Prosthetic components for removable restoration concepts will be available in the near future.

## Conclusion

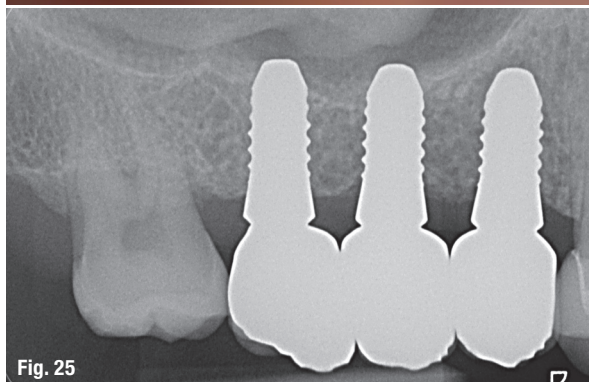
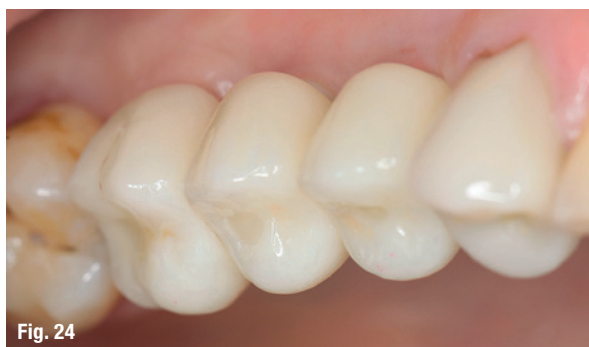
In summary, it can be stated that two-piece ceramic implants are a safe and biologically interesting alternative to existing titanium implants and represent a sensible addition to the implantological treatment spectrum of a dental practice. Thus, in order to reach clinical success with metal-free implants it is important to determine correct indications and to properly consider the ceramic-specific properties.

## contact

**Dr Frederic Hermann, M.Sc.**

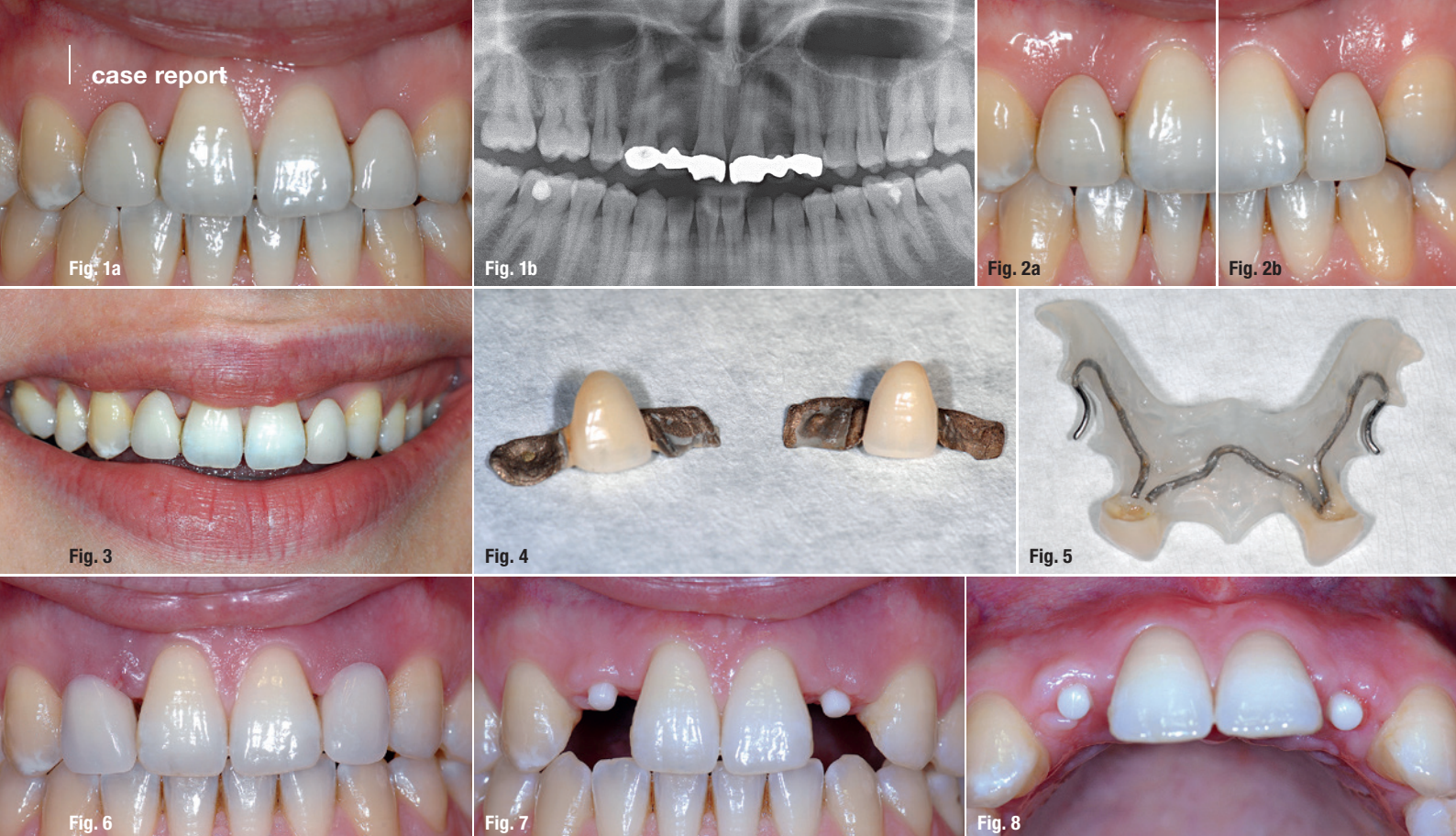
TEAM 15 – Dental Practice  
Poststr. 15  
6300 Zug, Switzerland  
info@team15.ch  
www.team15.ch

Author details



**Fig. 24:** Lateral view of the inserted implant crowns. **Fig. 25:** Radiographic control after insertion of the final prosthetics. The regenerated intraosseous defect in region #18 mesial has to be noted.





**Figs. 1a & b:** Initial clinical situation overview. **Figs. 2a & b:** Initial clinical situation of (a) tooth #12 and (b) tooth #22. **Fig. 3:** Lip-smile-line. **Fig. 4:** Former Maryland bridges. **Fig. 5:** Provisional aesthetic restoration with internal suspension clip. **Fig. 6:** Provisional restoration *in situ*. **Fig. 7:** One-piece ceramic implants prior to prosthetic placement. **Fig. 8:** Occlusal view.

# Aesthetic restoration in the incisal region

Michael Gahlert, Germany

**Dr Michael Gahlert is a fellow** of the International Team for Implantology (ITI) and has been specialising on the development and placement of ceramic implants. In this case report the aesthetic restoration of two maxillary incisors with ceramic implants is presented in detail. Dr Gahlert was supported by Otto Prandtner, dental technician at Dental Plattform and Dr Reza Saeidi Pour, prosthodontic specialist of the Dr Seehofer dental clinic, both from Munich, Germany.

## Case presentation

A 28-year-old female patient attended the practice with the desire to have her incisors, which by nature did not exist, replaced with implants. The patient had until then been wearing Maryland bridges. However, in the past years they had repeatedly been falling out of posi-

tion and thus regularly had to be reglued. Consequently, the patient was not satisfied with this solution anymore (Figs. 1–4).

In a thorough consultation, the patient was extensively informed about available restoration options and she decided for one-piece ceramic implants (PURE Ceramic, Straumann Group). In a first step a provisional aesthetic restoration with an internal clip was produced and could be integrated immediately after the former bridges had been removed (Figs. 5 & 6).

In the following implantological procedure autologous bone material was simultaneously buccally accumulated. The teeth of the provisional restoration were hollowed in order to prevent them from touching the freshly inserted one-piece ceramic implants (Figs. 7 & 8).



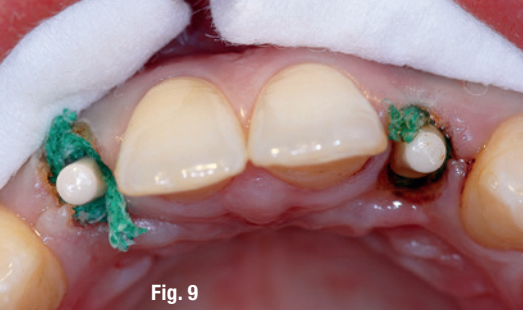

Fig. 9

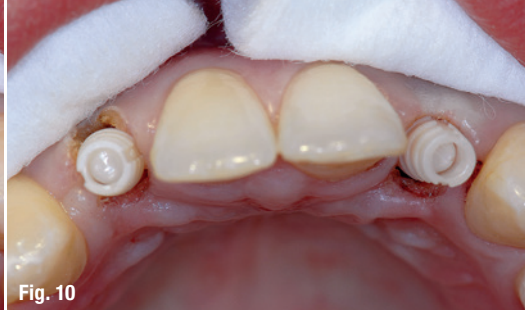

Fig. 10

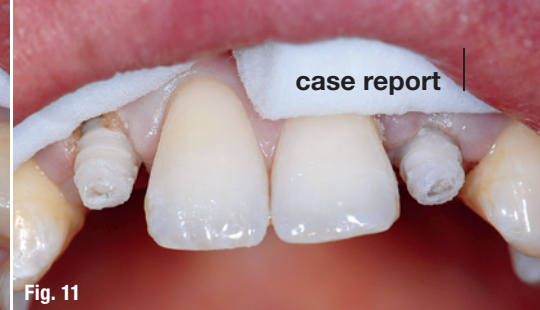

Fig. 11

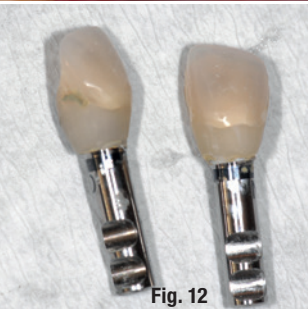

Fig. 12

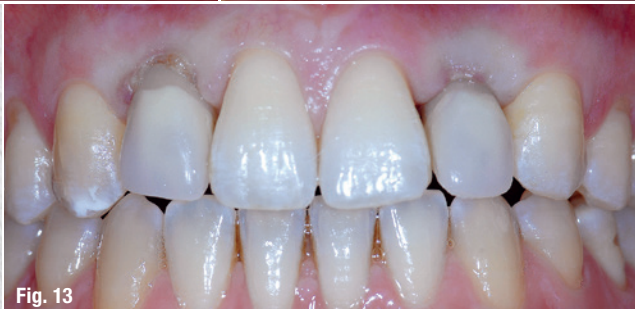

Fig. 13

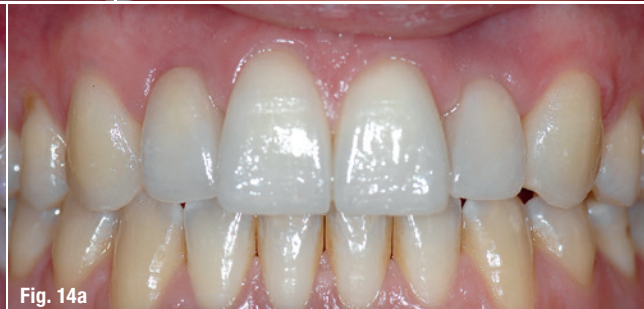

Fig. 14a

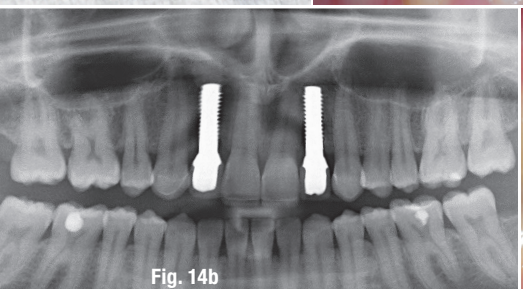


Fig. 14b

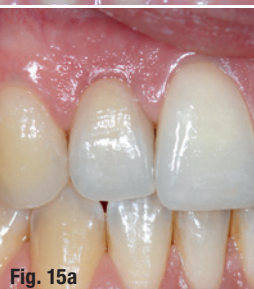

Fig. 15a

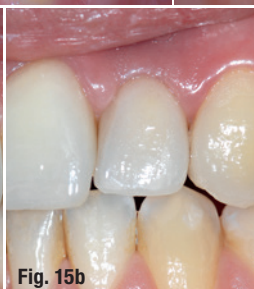

Fig. 15b

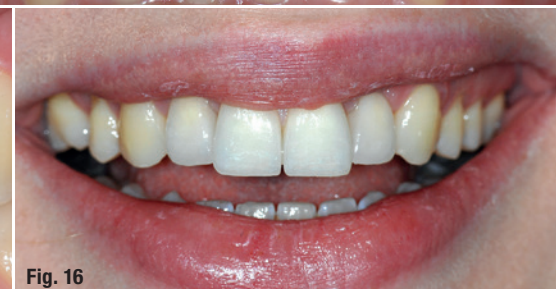

Fig. 16

**Fig. 9:** Gingival displacement. **Fig. 10:** Fitted plastic temporary copings. **Fig. 11:** Shortened temporary copings. **Fig. 12:** Final chairside provisional restorations on laboratory implant analogues. **Fig. 13:** Chairside provisional restoration *in situ*. **Figs. 14a & b:** Definitive restorations. **Figs. 15a & b:** Final state of (a) tooth #12 and (b) tooth #22. **Fig. 16:** Lip-smile-line with final restoration. **Fig. 17:** Patient portrait with lip-smile-line.

After a healing period of three months the implants were prepared for the provisional crowns. In order to do so the peri-implant gingiva had to be displaced with retraction threads. Excess gingiva was removed with an electrotom on the palatal side (Fig. 9).

Industrially produced temporary copings (Straumann Group) were then put on the implant fixture and shortened accordingly (Figs. 10 & 11). This so-called snap-on method facilitates the prosthetic handling and is also used for taking impressions with appropriately prefabricated impression caps.

The prosthetic teeth that had been removed from the provisional restoration were in a further step glued onto

the caps and transferred to the chairside provisional restoration. After forming the pink aesthetics, the definitive impressions were taken and the full-ceramic crowns were produced. Finally, the restorations were placed using glass ionomer cement (Ketac™ Cem, 3M ESPE) as definitive mounting material (Figs. 12–14).

## Conclusion

Ceramic has become a material of choice when dental implants are concerned. Especially as the teeth to be restored were located in the aesthetic zone the patient's decision for ceramic implants proved to be the correct choice producing a satisfying outcome for practitioner and patient (Figs. 15–17).

## contact

**PD Dr habil. Dr med. dent. Michael Gahlert**  
Hightech Research Center of Cranio-Maxillofacial Surgery  
Department of Biomedical Engineering  
University of Basel, Switzerland

Private Dental Clinic  
Theatinerstraße 1  
80333 Munich, Germany  
[www.drgahlert.com](http://www.drgahlert.com)



Author details

Fig. 17



# Immediate placement in the maxillary aesthetic zone

Dr Saurabh Gupta, India & Dr Sammy Noubissi, USA

**This particular case report details** the immediate replacement procedure of a previously unsuccessfully endodontically treated maxillary central incisor with a one-piece zirconia implant. Atraumatic extraction of the incisor was followed by a curettage procedure to remove any fragments of peri-apical granuloma.

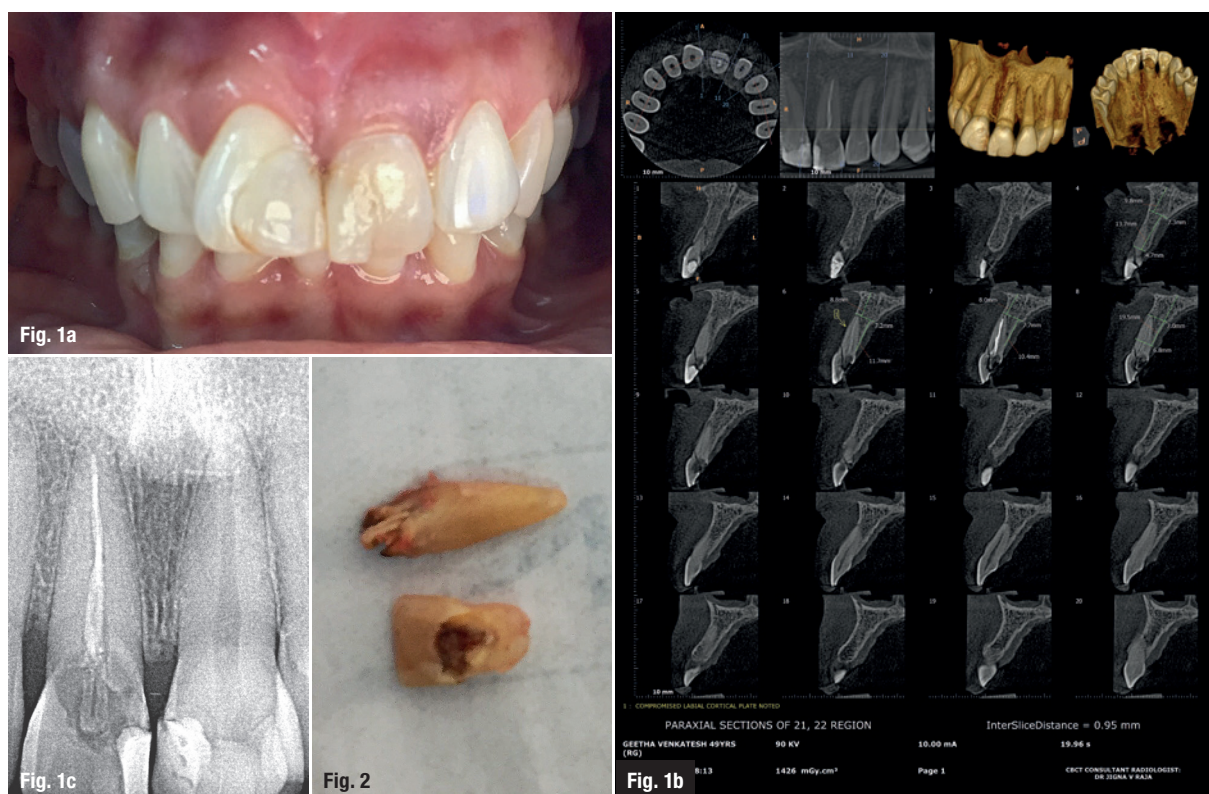
Immediate placement of the implant (one-piece ZiBone zirconia, COHO) with good primary stability was accomplished and the implant was then restored with a zirconia crown four months later. The follow-up after a year found effective osseointegration with optimum function and form.

## Case presentation

The patient was a 36-year-old woman, who came for a dental check-up because she was suffering from pain

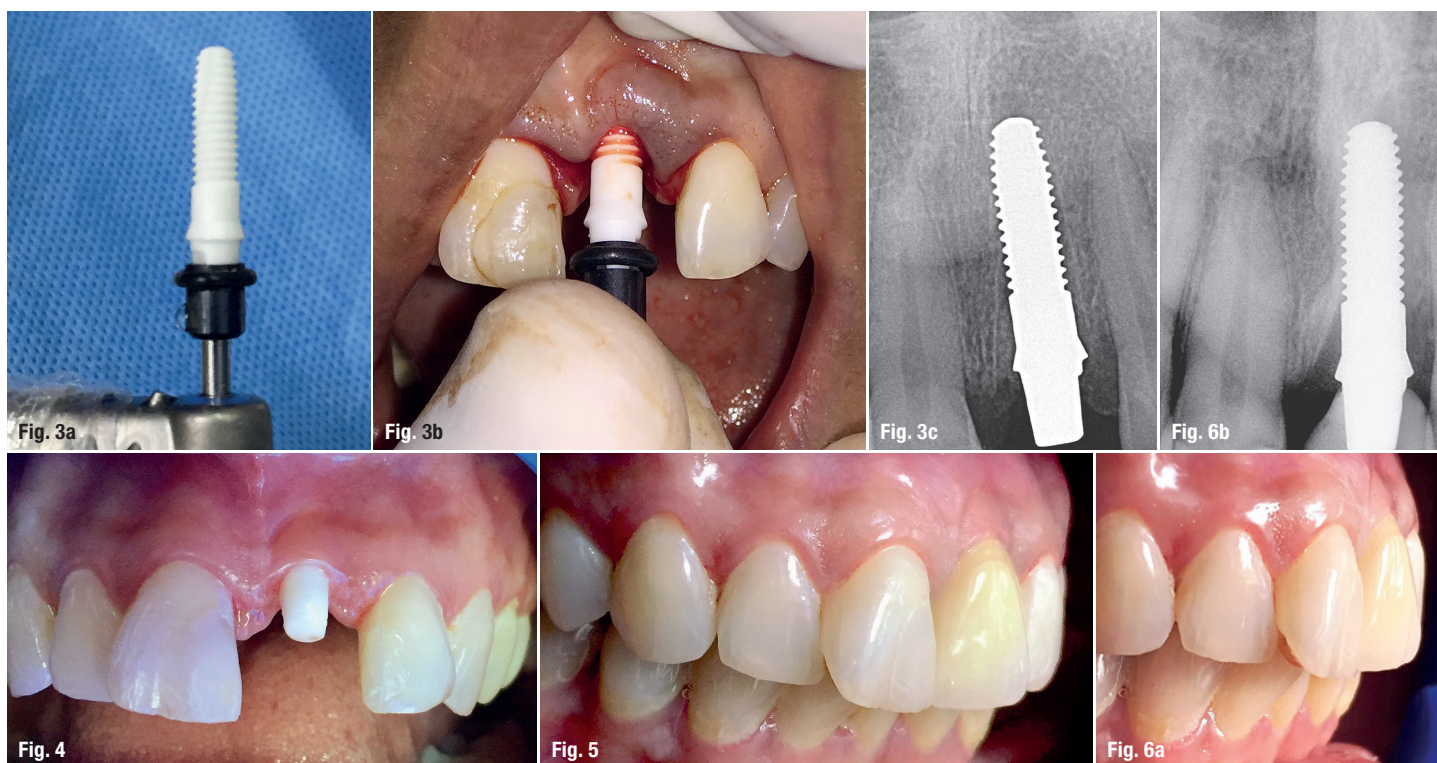in the left maxillary anterior tooth area. The pain, according to her, was sudden at the start and it worsened upon biting. The clinical examination of tooth #21 revealed inflammation, pain on percussion and fractured tooth at the cervical margin.

The tooth had been endodontically treated three years before and had not gone through rehabilitation earlier. Radiographic examination showed a fractured crown that had minor root resorption with an associated peri-apical infection (Figs. 1a–c). There was presence of sufficient bone width and height as was radiographically and clinically verified. The poor prognosis for endodontic retreatment was explained to the patient and she requested more conclusive treatment. It was then decided that the tooth needed to be removed and immediately be replaced with a one-piece zirconia implant.



**Fig. 1a:** Pre-op clinical photograph of tooth #21. **Fig. 1b:** CBCT scan. **Fig. 1c:** Radiograph of tooth #21. **Fig. 2:** Extracted tooth #21.





**Figs. 3a–c:** One-piece ZiBone zirconia implant (Ø 4.0mm, length 12.0mm). **Fig. 4:** Healing state after four months. **Fig. 5:** Restoration of tooth #21 with a zirconia crown. **Figs. 6a & b:** One-year post-op situation and radiograph.

## Surgical procedure

Thorough ultrasonic scaling and maintenance were done before extraction and placement of the implant. Under local anaesthesia with lidocaine (Lignox, Indoco with adrenaline of 1:200,000) atraumatic extraction of tooth #21 was performed with the use of a periosteal elevator (Fig. 2). In-depth debridement of the extraction socket was performed using bone curettes for the removal of granulation tissue.

The next procedure was the preparation of the osteotomy sites using a pilot drill and verification followed with the use of direction indicators. Consecutive drilling was then performed all the way to the last implant dimension and one ZiBone zirconia implant (Ø 4.0mm, length 12.0mm) was placed in region #21. Primary stability was accomplished at approximately 35Ncm (Figs. 3a–c).

Then, particulate bone grafting material was placed with the objective of filling the gap between the tooth socket and implant. The implant was secured in place using a Geistlich Bio-Gide collagen membrane (Geistlich Biomaterials) and the region was sutured with 3/0 black silk suture thread. It was decided to place the crown at a later stage. The immediate postoperative radiograph showed a parallel and properly placed implant.

For postoperative home care, instructions involved tooth-brushing, rinsing with 0.12% chlorhexidine, and

taking 400 mg of metronidazole and 500 mg of amoxicillin t.i.d. for five days, as well as three days of paracetamol. Removal of the sutures was done after seven days, at which time the wound was seen to be healing well.

Impressions were taken four months later and the zirconia crown was subsequently seated on the implant that had replaced tooth #21 (Fig. 4). Crown occlusion was confirmed with articulating paper of 12µ in thickness (Fig. 5).

The postoperative review one year later showed that there was no indication of mobility, bone loss, peri-implant laceration or paraesthesia. Furthermore, there was no indication of inflammation of the soft tissue (peri-implant) surrounding the site (Fig. 6).

## Discussion

Considerations for using zirconia implants include the material's aesthetic advantages: no galvanic reaction and lower risk of inflammation in comparison to the accidental introduction of titanium particles to the osteotomy site.<sup>1–3</sup>

After 20 years, there is evidence suggesting that zirconia-based implants are highly biocompatible, in addition to having advantageous physical properties. Further evidence has shown that zirconia has the ability to withstand sustained loads, which implies that zirconia implants are also suitable for replacing posterior teeth.<sup>4</sup>



In this case, metallic implants were not desired by the patient, and for that reason, the single-piece zirconia implant was decided on.<sup>5,6</sup> The absence of a micro-gap with one-piece implants in comparison to two-piece implants guarantees minimum microleakage and minimal bacterial colonisation, which may otherwise possibly result in bone loss.<sup>7</sup>

Conventional protocols for implant placement, as well as loading in areas with periapical infection, means several months of delay in the implant procedure after extraction, to effectively avoid infecting the surfaces of the implant.<sup>8</sup> Nevertheless, occurrence of unintentional bone loss is possible while waiting for lesion resolution; this may compromise function and aesthetics. The amount of resorption of crestal bone after tooth extraction can extend to 23 per cent in six months, which may compromise the soft- and hard-tissue structure. Systematic review results advocate that it is possible to place implants in sites with periapical and periodontal infections.<sup>9,10</sup>

This case entailed the performance of exhaustive surgical debridement before placement of the dental implant. Guided bone regeneration (GBR) was performed as well, for filling of the socket-implant gap. These steps were followed based on the evidence provided by Waasdorp et al.'s systematic review.<sup>11</sup>

A randomised multicentre controlled trial observed no clinical variances in complications, implant survival and changes in the marginal bone levels when placing single implants early, conventionally or immediately.<sup>12</sup>

A meta-analysis and systematic review that studied the procedures for immediate placing and loading/restoring single implants in frontal maxillary regions provided inspiring outcomes of over 97.9% and 99.0% implant survival rates, respectively.<sup>13</sup>

Both prospective and retrospective studies have been performed, and they supported the immediate placement of implants even in areas with periapical pathology. A reflective analysis (67.3 months of follow-up) of 418 immediately placed implants displaying periapical pathology established an increasing 97.8% survival rate<sup>14</sup>.

Another reflective study compared the survival rates of immediate implants placed in sites with and with no periapical pathology. Among the 922 implants, 285 were implanted into sockets with periapical radiolucencies (19.75 months of follow-up).<sup>15</sup> The survival rates of the control and study groups were at 97.5% and at 98.7%, respectively, which happened to be statistically insignificant.

Remarkably, a statistically greater degree of failure has been found for implants placed next to retained teeth with periapical lesions. In a prospective clinical controlled trial

by Siegenthaler et al. in which 13 immediate implants were implanted in areas that exhibited periapical pathology and 16 immediate implants were placed in healthy areas, there was no difference observed between radiographic and clinical parameters.<sup>16</sup> Primary stability was achieved for both groups.


Jung et al. placed immediate implants into areas both with and with no periapical pathology and reported a 100% survival rate five years after the placement.<sup>17</sup> It is vital to keep in mind that studies like these have emphasis on the elimination of pathology both chemotherapeutically and mechanically while supporting GBR wherever it is required.

Surfaces of zirconia implants tend to accumulate less bacteria in comparison to titanium surfaces. This could avert an inflammatory gingival reaction that could aggravate an existing periapical lesion. Reduction in the bacteriological load promotes the biological width formation and mucosal closure that could thwart any apical bacterial colonisation.<sup>18-21</sup>

## Conclusion

The immediate placement of a zirconia implant could well benefit areas of existing periapical infection, provided that the infected site undergoes a thorough surgical debridement and GBR is used if necessary, and there is adequate antibiotic coverage and sufficient postoperative maintenance.

*Editorial note: The authors disclosed that they have no financial or other competing interests.*



## contact

### Dr Saurabh Gupta

Oral & Maxillofacial Surgeon & Implantologist  
IAOCI Educational Director  
Bangalore, India  
Tel.: +91 9916203455  
saurabh@iaoci.com



### Dr Sammy Noubissi

DDS, MS, PA  
International Academy of  
Ceramic Implantology  
801 Wayne Avenue, Suite #G200  
Silver Spring, MD 20910, USA  
sammy@iaoci.com





The innovative specialist society for modern metal-free implantology

## Become a member now!

### Advantages

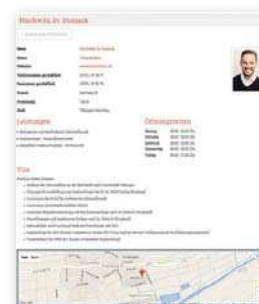

#### Public relation work

Benefit from a strong community that supports your practice marketing through their public relation measures.

#### Society's website including member profiles

Use the individualised member homepage and profit from a personal profile which ISMI provides free of charge to all active members. The patient platform of ISMI offers information for patients as well as a "dentists search & find" option and connects patients to the individual member homepages.

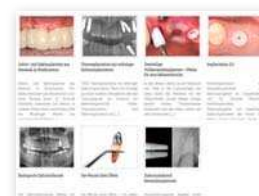

#### Congress participation discount

Come and join us! Attend the Annual Congress of ISMI and receive further education provided by our partners for reduced participation fees for all ISMI members.

#### Online specialist archive

Get exclusive access to ISMI's comprehensive online archive. Discuss with experts and colleagues all questions concerning metal-free implantology and enjoy free access to the online archive and its subject-related training videos and case reports.



#### Newsletter

The ISMI newsletter informs you of the latest scientific trends, products, and events. It also provides user reports as well as a wide range of information and tips on the subject of metal-free implantology.

#### Specialist magazine

As a member of ISMI, your membership fee includes a subscription of the independently published English magazine "ceramic implants—international magazine of ceramic implant technology". Published twice a year, the magazine offers specialist articles and event reports as well as industry- and science-related news from the international world of metal-free implantology. In addition "ceramic implants" provides information on companies and their newest products.

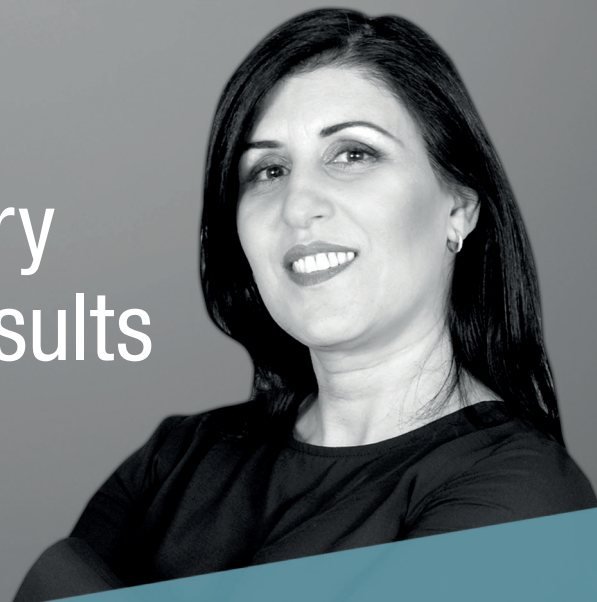

Become a member now!



# Change is mandatory for extraordinary results

Revital Shabtai, VP Marketing, TAV Dental

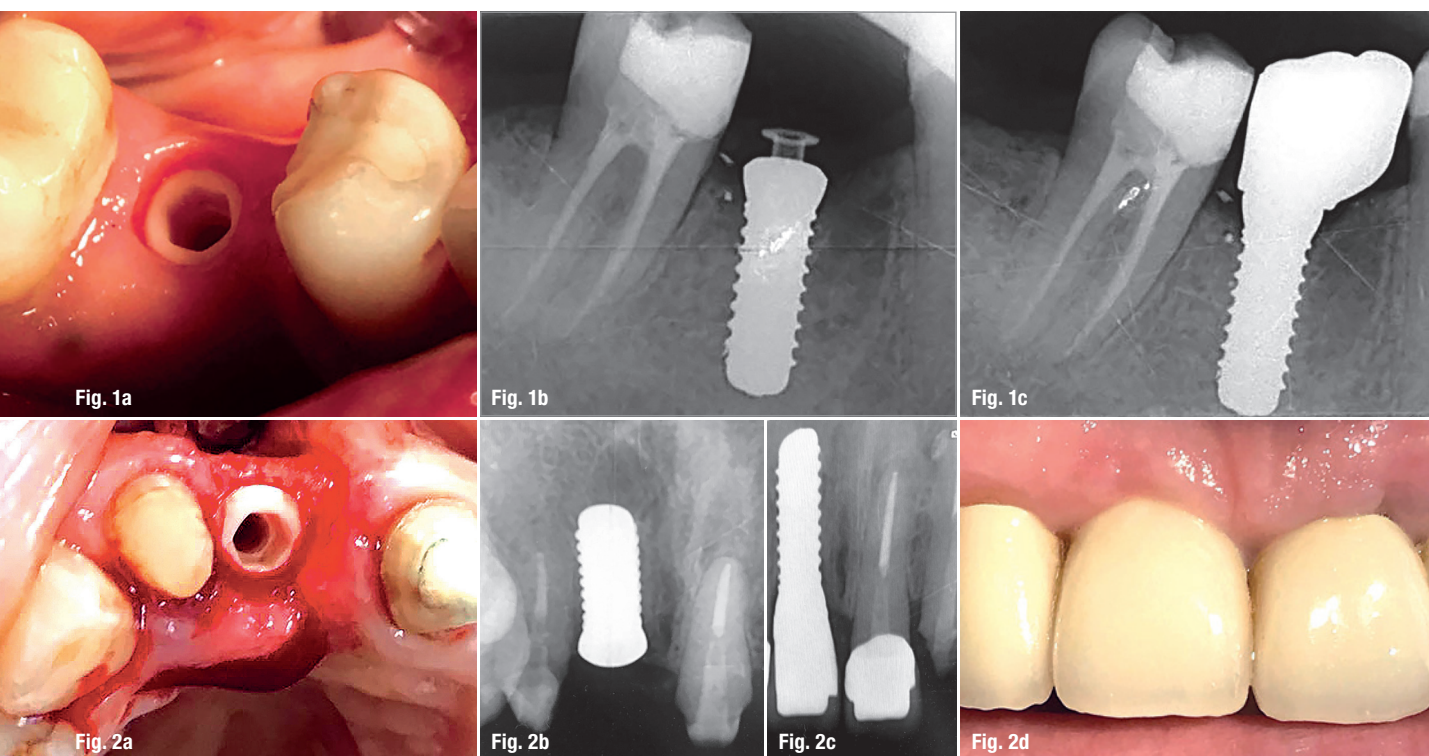


It is true, titanium was the gold standard in oral implantology for many years, however time is changing and so are our patients' needs and demands. High aesthetic standards and increasing incidences of titanium sensitivities along with a rising demand for metal-free reconstructions have led to the search for an alternative material.

Zirconia implants were introduced into dental implantology as an alternative to titanium implants (Figs. 1a–c). Zirconia seems to be a suitable implant material because of its tooth-like colour ensuring high aesthetic results, excellent mechanical properties, osseointegration

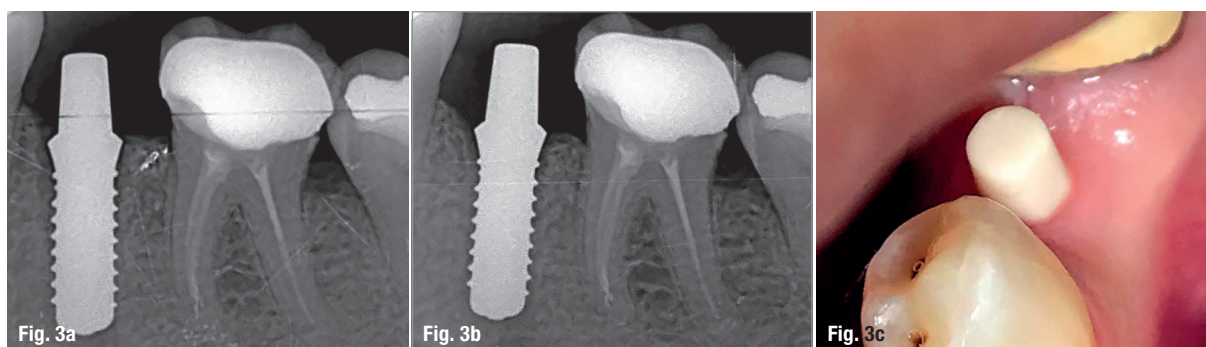
and clinical advantages superior to titanium implants (Figs. 2a–d).

When it comes to innovation in implant dentistry, new technologies like patient-customised CAD/CAM abutments, drill guides and digital treatment planning have been implemented. When it comes to dental implants, there are those who believe that research has come to the end of the road. We think different, we think zirconia implants are the new road the market is going to take (Figs. 3a–c). New improvements and advancements will drive value to our customers.



**Figs. 1a–c:** Tooth #46 three months after implant placement, screw-retained restoration with monolithic zirconia crown. **Figs. 2a–d:** Tooth #11: Two-piece zirconia implant with cemented zirconia crown.





**Fig. 3a:** Tooth #35: Immediate implant placement after tooth extraction. Radiograph of the day of surgery. **Figs. 3b & c:** Situation after four months.

As our focus is to create immense value with our zirconia implants, we are committed to bring innovation to the dental market and to substantially improve the treatments of patients world wide through continuous advancements. This is why we are soon launching a new generation of zirconia implants, designed by a highly professional team, manufactured by high-end CIM technology, resulting in state-of-the-art products. FDA approval is expected soon.

Let us together redefine implant dentistry for the benefit of the patients.

*All figures: © Dr George Pamborides, DMD at Nicosia Dental Clinic, Associate Fellow AAID, IAOCI member*

### contact

#### TAV Dental

Shlomi, Israel

Tel.: +972 4 9808615

info@tavdental.com

www.tavdental.com

AD



# Strong. Aesthetical. Metal-free.

✓ Two-piece, reversibly screw-retained    ✓ 100% metal-free    ✓ Strong connection with VICARBO® screw

An innovation from Switzerland based on 10 years of experience in the development of ceramic implants.

[www.zeramex.com](http://www.zeramex.com)

## ZERAMEX®

# Ceramic implants in anterior dental restoration

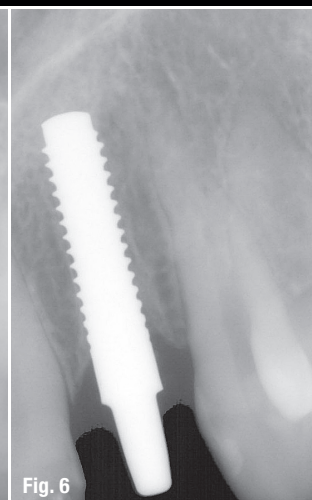
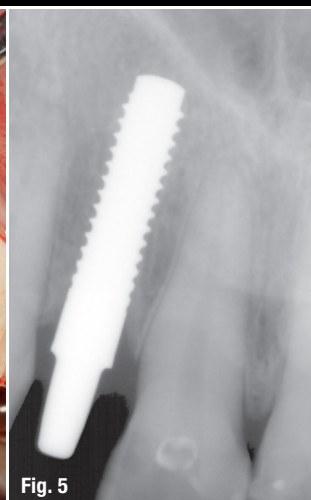
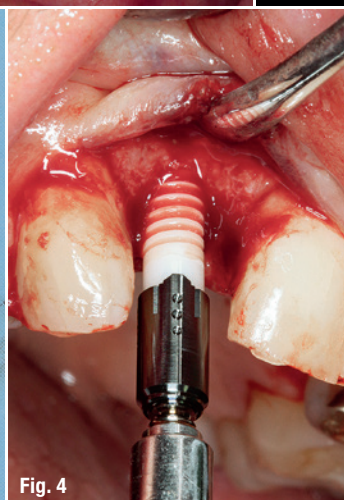
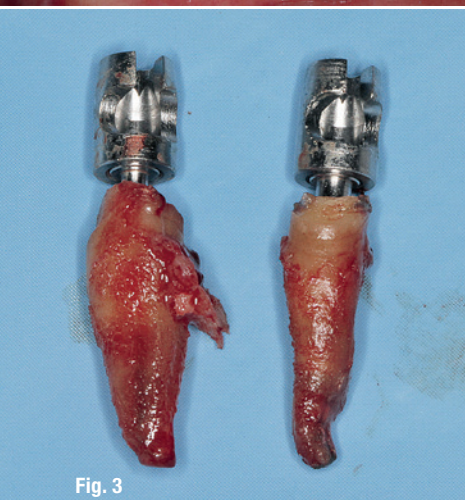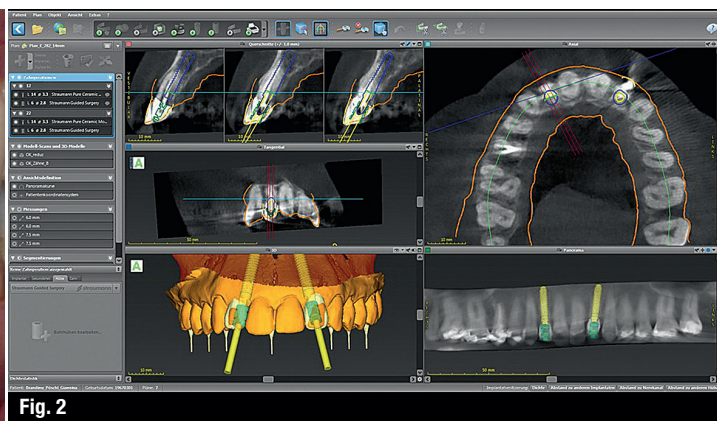
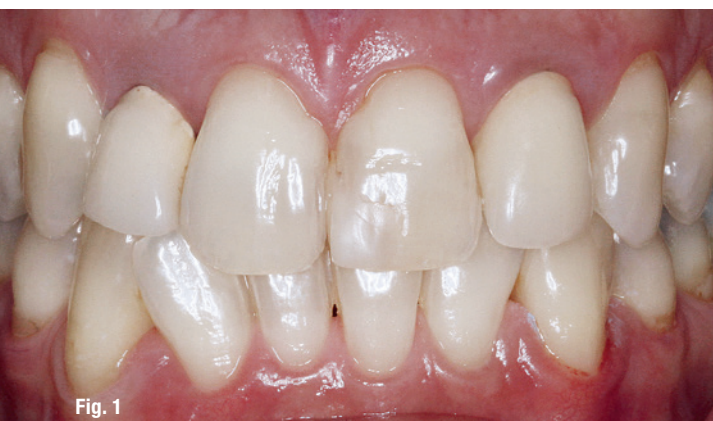Dr Franz-Jochen Mellinghoff, M.Sc., PhD, Germany

## Initial situation

A 39-year-old female patient of good general health attended our practice for a consultation. She came from a small town approximately 70km from our practice and had found out beforehand via the Internet which dentist in the area offered ceramic implants. The patient was prepared to make the long trip to reach us because she was worried that the apicectomy proposed by her own dentist would once again involve introducing new foreign material (sealing material for the apical closure of

the root canals) into the bone. She had thus decided on having the root-filled teeth and associated metal-ceramic crowns, as well as the periapical granulomas, removed. She clearly and unequivocally communicated her desire for ceramic implants.

In our practice, particular importance is attached to an informative initial consultation with new patients. Expectations of both patient and therapist—the “shared therapeutic vision”—should be addressed in this consultation. The patient in this case was looking for very



**Fig. 1:** Initial situation. **Fig. 2:** An evaluation of the CBCT scan shows adequate conditions for inserting ceramic implants. **Fig. 3:** Extracted lateral incisors. **Fig. 4:** Implantation of Straumann PURE Ceramic Implant (diameter: 3.3 mm; length: 12.0 mm). **Figs. 5 & 6:** Radiographs showing the two ceramic implants inserted into the prepared alveoli.



good function, a high level of aesthetics and well-tolerated materials. Our expectations were constructive co-operation covering a comprehensive history, very good diagnostic options, and high-quality surgical and dental technology products. All of these are integrated in a programme of oral hygiene management developed for implant patients. Planning involves detailed explanation of the intended treatment, photographs, models and radiographs (Fig. 1).

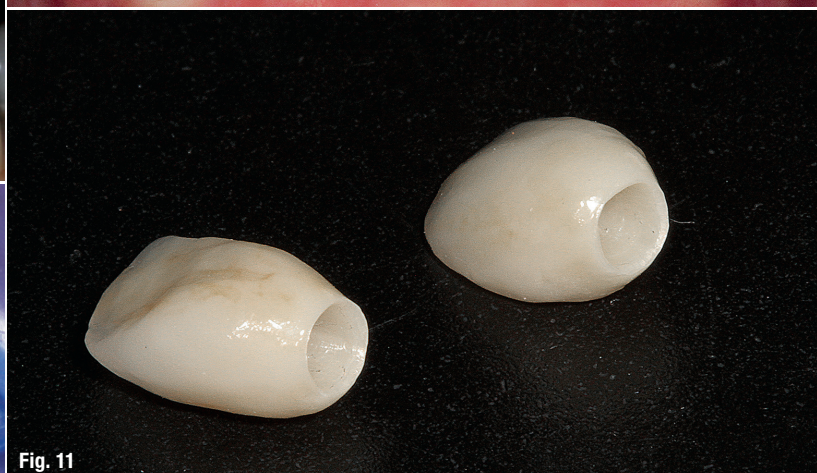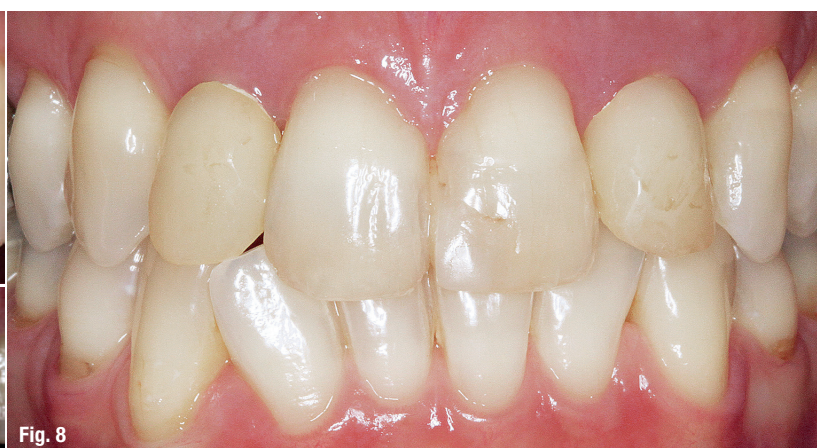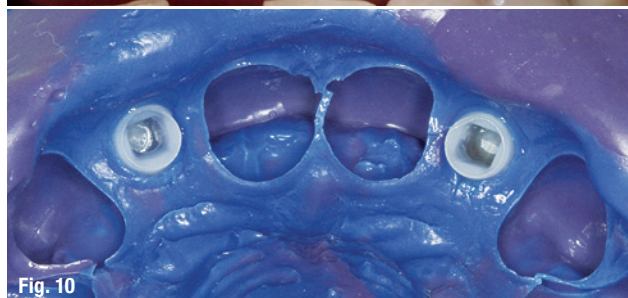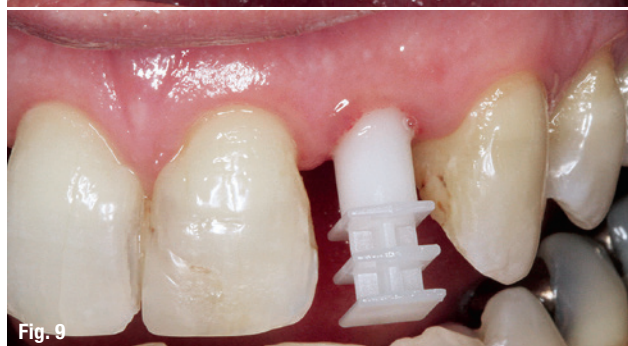
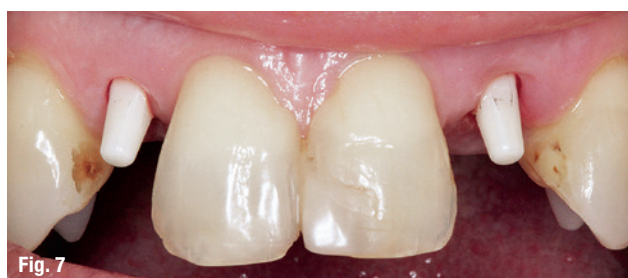## Therapy schedule

The patient's dental chart revealed full dentition, partly restored with resin composite filling materials. Teeth #12 and 22 had been crowned after endodontic treatment. The patient complained of problems in the maxillary region between teeth #13 and 23. Pain on pressure was reported in response to digital pressure (thumb and index finger) in the apical region of teeth #12 and 22, differing clearly from the adjacent regions. A clinical diagnosis of suspected apical osteitis was made and was confirmed in the radiograph and cone beam computed tomography (CBCT) scans subsequently taken.

After being given an explanation and time for consideration of the various options, the patient decided on extraction of teeth #12 and 22. We selected immediate implantation for the restoration of regions #12 and 22. Good experiences with this method allowed us to suggest the prospect of a shorter treatment period and a high-quality aesthetic outcome to the patient. After evaluation of the CBCT scan, we were able to meet her request for the provision of ceramic implants (Fig. 2).

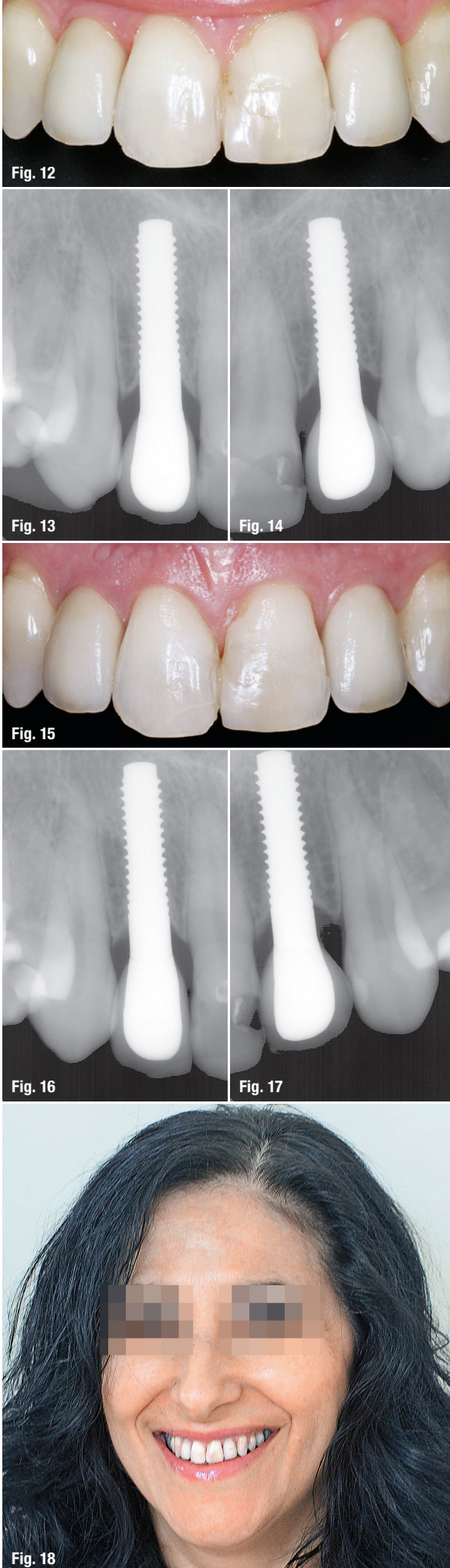
## Surgical procedure

The two lateral incisors were removed using a Benex extractor (Helmut Zepf Medizintechnik; Fig. 3). This procedure reduced the risk of alveolar damage, particularly damage to the vestibular alveolar wall. The alveoli were freed from the inflamed apical tissue by means of intensive curettage. Two monotype, reduced-diameter Straumann PURE Ceramic Implants of 3.3mm in diameter and 12.0mm in length were implanted using a surgical drill template (Fig. 4). The two ceramic implants could then be inserted into the prepared alveoli at a torque of 35Ncm (Figs. 5 & 6).



**Fig. 7:** Chairside temporisations. **Fig. 8:** Long-term temporary restorations. **Figs. 9 & 10:** The impression for permanent crowns was taken using a single tray with polyether and impression caps compliant with the system. **Fig. 11:** Crowns manufactured on the basis of milled zirconium dioxide copings veneered with feldspathic ceramics.





**Figs. 12–14:** Secure outcome after cementation with glass ionomer cement.

**Figs. 15–17:** Periodontal situation after two and a half years. **Fig. 18:** Patient satisfied with the outcome; further development will be recorded.

After suturing, impression posts were used to take an impression in order to create long-term temporary restorations. Chairside temporisations were used until these were ready (Fig. 7). With the long-term temporary restorations, the patient was able to go to work and her ability to communicate was not restricted in any way either (Fig. 8). The healing process was problem-free.

## Prosthetic procedure

The impression for the permanent crowns was taken using a single tray with polyether and impression caps compliant with the system (Figs. 9 & 10). The crowns were manufactured on the basis of milled zirconium dioxide copings veneered with feldspathic ceramics (Fig. 11). Cementation with glass ionomer cement produced a secure outcome (Figs. 12–14). Treatment was completed by a functional test.

## Treatment result

The outcome of the treatment met the planned specifications in terms of both aesthetics and function. The minimally invasive extraction meant that both hard- and soft-tissue were preserved to the maximum extent possible. Comparison of the periodontal situation after two and a half years on the basis of photographs and radiographs indicated a very good long-term prognosis (Figs. 15–17).

## Conclusion

The patient asked for a non-metal prosthetic implant. As a result of the limited spatial conditions, ceramic implants with a diameter of 3.3mm were selected. The detailed planning and its implementation meant that it was possible to achieve a more than satisfactory outcome for the patient, the practice and the dental laboratory (Fig. 18). The patient decided to remain in our oral health programme despite the additional travel involved. This meant that we would be able to record further developments.

## contact

**Dr Franz-Jochen Mellinghoff**

**M.Sc., PhD**

Pfauengasse 14

89073 Ulm, Germany

Tel.: +49 731 62158

jochen.mellinghoff@dr-mellinghoff.de

www.dr-mellinghoff.de

Author details





# VISIONS IN IMPLANTOLOGY

1<sup>ST</sup> FUTURE CONGRESS  
FOR DENTAL IMPLANTOLOGY

28 + 29 SEPTEMBER 2018

**NEW**  
**SAVE THE**  
**DATE**

48<sup>TH</sup> DGZI INTERNATIONAL ANNUAL CONGRESS  
HILTON HOTEL DÜSSELDORF, GERMANY

**WWW.OEMUS.COM**

OEMUS MEDIA AG · Holbeinstraße 29 · 04229 Leipzig · Germany · Tel.: +49 341 48474-308 · Fax: +49 341 48474-290 · event@oemus-media.de

**DGZI**  
Deutsche Gesellschaft für  
Zahnärztliche Implantologie e.V.

## SDS Swiss Dental Solutions

### Ceramic implant forms with osteogenic functionality

While SDS ceramic implants were being applied routinely at the Swiss Biohealth Clinic of Dr Volz, the experience and knowledge that were gained there led to the development of a new kind of implant. The improved biocompatibility of zirconium dioxide implants, together with the bone- and soft-tissue growth associated with it have provided new options for implantation wherever pronounced oval alveoli need to be treated, or multiple rooted teeth must be replaced. To this end, the implant ranges "oval" and "balcony" were developed, available in different diameters and lengths, both as single pieces and in two parts, and which were able to optimally close the alveoli, especially with emergency implantations.

The new SDS "sinus implants" (Fig.) were developed specifically for sinus lifting. Due to the increased biocompatibility of  $ZrO_2$ , bone growth is

also optimally exploited for this indication. In the apical area of the sinus implants, a plate is introduced, which on the one hand spares damage to the Schneiderian membrane upon sinus lifting, and on the other forms a large cavity under the plate due to an umbrella effect. The actual implant serves as a tent pole in this cavity, which creates optimal conditions for inward bleeding and the bone regeneration which results from this. Bone graft material is not necessary in almost all cases. The sinus implants are also available in various diameters and lengths.



**SDS Swiss Dental Solutions AG**  
Zollstr. 8  
8280 Kreuzlingen, Switzerland  
[www.swissdentalsolutions.com](http://www.swissdentalsolutions.com)

## Straumann

### PURE Ceramic Implant System

Nothing is more winning than a light-hearted and happy smile. With the PURE Ceramic Implant System even very demanding patients can smile with confidence according to the principle "Discover natural PURE white. Love your smile."

With this implant system, dentists can grant their patients the best aesthetic, natural and solid treatment. Patients will benefit from all the highly aesthetic advantages of a natural ceramic implant—ivory-coloured like a natural tooth root and even in cases of thin gingiva biotypes not shining through. No compromises on aesthetics, reliability or the most natural choice of material are necessary. Further they can rely on high-performance zirconia ceramic material being even stronger than the gold standard, grade 4 titanium implants.

The Straumann® PURE Ceramic Implant System is the result of more than 12 years of relentless research and development until the ceramic implants complied with the company's premium quality standards. Swiss quality and precision, strength, clinical success and flexible treatment protocols are combined in an innovative solution that helps dentists meet the needs of their patients.

**Institut Straumann AG**  
Peter Merian-Weg 12  
4052 Basel  
Switzerland  
[www.straumann.com](http://www.straumann.com)





## CAMLOG

### Metal-free aesthetic restorations from implant to crown

CAMLOG's full range of ceramic implants and prosthetic components supports metal-free aesthetic restorations from the implant to the crown. CERALOG implants offer high predictability and exceptional aesthetic properties. The range includes ivory-coloured one- and two-piece zirconia implants and reversible screw-retained abutments. In the application they are close to the common standard of titanium implants. Outstanding features of the system are the biocompatibility of the high-performance material, the reversibility of the screw-retained prosthetic components and the achievement of highly aesthetic restorations. CAMLOG has established a close interface to DEDICAM and thus to individual CAD/CAM prosthetic solutions. The expansion of the

product range opens new patient-oriented treatment options for clinicians. Once again emphasizing the company's innovative strength.



**CAMLOG Biotechnologies AG**  
Margarethenstr. 38  
4053 Basel  
Switzerland  
[www.camlog.com](http://www.camlog.com)



## COHO Biomedical Technology

### The next generation of implants



COHO recognizes that nowadays patients are not satisfied merely with the function of restorations but also demand aesthetics. With this in mind, a completely aesthetic solution for implant treatments was developed: ZIBone ceramic implants for both function and aesthetics, ceramic drills for cutting efficiency and reducing heat generation and our milling centre for producing fixed temporary and Zirconia ceramic prostheses ensuring accurate fit. Zirconia is a material of choice in terms of aesthetics, biocompatibility and mechanical properties.

All of our products must go through stringent quality control to make sure that they perform according to specification and patient safety requirements. ZIBone ceramic dental implants were approved by U.S. FDA, CE and TFDA. Their cylindrical body and conical tip design enables them to achieve the

highest possible primary stability. The fine neck thread increases the bone contact area and initial stability. Threads in the implant body and wide pitch design provide stability and promote osseointegration.

**COHO Biomedical Technology Co., Ltd.**  
No. 21 Dafeng Street, Luzhu District  
Taoyuan City 33860, Taiwan  
[www.zibone.com](http://www.zibone.com)

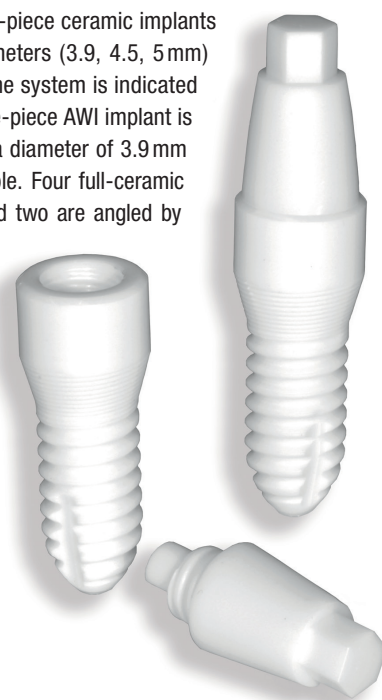
## WITAR

### Biocompatible ceramic implant

Metal-free, biocompatible and aesthetic: Ceramic implants have gained popularity among dentists and patients. Building upon this trend, WITAR offers a new AWI implant system for transgingival healing. With this, the company promises an implant treatment that is safe, cost-efficient and simple. The two-piece system that has been developed and patented recently is made from Y-TZP ceramic and offers a reliable and easy handling. Treatment steps had been optimised for an increased safety and biocompatibility. At the same time, treatment costs and time could be reduced.

The implant system consists of nine two-piece ceramic implants that are available in three different diameters (3.9, 4.5, 5 mm) and lengths (8, 10, 12 mm). With this, the system is indicated for all bone classes. Additionally, the one-piece AWI implant is available in two sizes (10, 12 mm) with a diameter of 3.9 mm and can be used in the anterior mandible. Four full-ceramic abutments of which two are straight and two are angled by 15 degrees, belong to the system as well. Furthermore, the system includes a sterilisation box, surgical tray with milling machines made from ATZ high-performance ceramics, and turning tools.

**WITAR Consulting GmbH**  
Rodenkirchener Straße 148  
50997 Cologne, Germany  
[www.witar.de](http://www.witar.de)





## TAV Dental

### State-of-the-art zirconia dental products

TAV Dental offers both one-piece and two-piece screw-retained zirconia implants. The passion behind developing zirconia implants is to meet nowadays patient's needs, which are more health conscious and have higher aesthetic demands than ever before. As Oded Ben Shabat, TAV Dental CEO, stated: "If today you can have zirconia implants at a competitive price with the same osseointegration, the same stability together with all clear clinical advantages such as soft tissue integration and low plaque adhesion, why should a doctor still buy titanium implants." TAV Dental will soon launch a new generation of zirconia implants

designed by a highly professional team, manufactured by high-end CIM technology and thus resulting in state-of-the-art products, that will be supported by CAD/CAM restoration. "We are very excited about the release of this new generation of implants and we are expecting to receive the regulatory approvals soon," stated Oded Ben Shabat.

**TAV Dental**  
**Shlomi, Israel**  
[www.tavdental.com](http://www.tavdental.com)

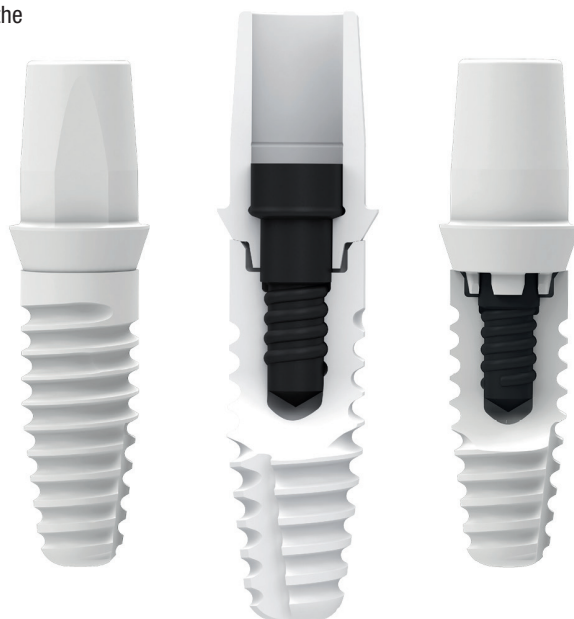## Dentalpoint

### Bolt-in-tube—the simple and strong ceramic connection

ZERAMEX® XT abutments are screw retained. The key component of the connection is the VICARBO® screw which acts as a bolt by firmly fixing the abutment to the implant. It is a fitting screw and safely absorbs occlusal forces. Thanks to its soft surface, the screw precisely conforms to the thread profile of the ceramic implant upon tightening.

The abutments are available in straight and angular versions. All abutments are fitted with a "four merlon"-platform which offers four positioning options. The VICARBO® screw seals the implant hole, and thus prevents the exchange of potentially bacteriologically contaminated liquids between implant and oral cavity caused by micromovement. The ZERAMEX® XT implant offers high prosthetic flexibility as it is placed supracrestally with a variable placement depth ranging from 0.6 to 1.6 mm.

**Dentalpoint AG**  
**Bodenackerstr. 5**  
**8957 Spreitenbach**  
**Switzerland**  
[www.zeramex.com](http://www.zeramex.com)



# BECOME AN AUTHOR

for ceramic implants—international  
magazine of ceramic implant technology

Interdisciplinary and close to the market



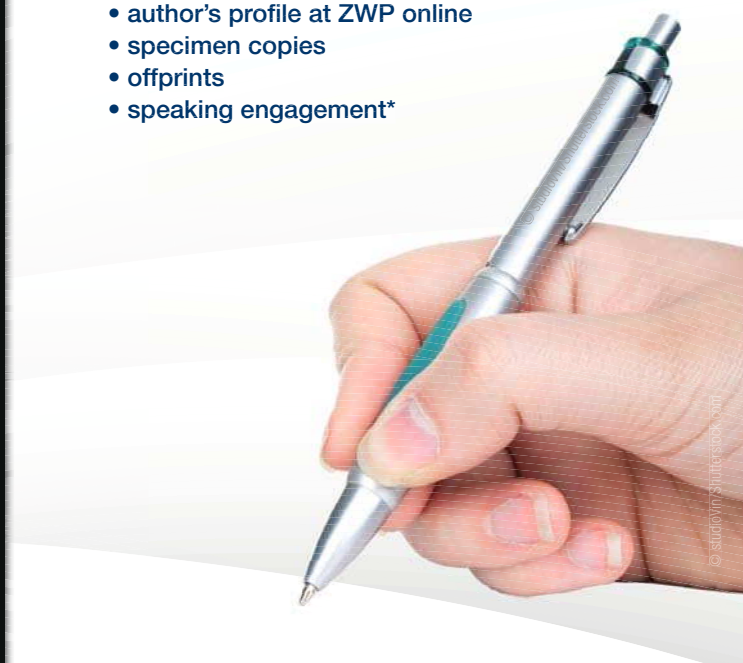
www.oemus.com



Become part of a successful  
network and benefit from a  
wide reach and high level of  
awareness

Your benefits:

- author's profile at ZWP online
- specimen copies
- offprints
- speaking engagement\*



\*according to the required profile

Fax to **+49 341 48474-290**

☐ Yes, I want to become an **author** for ceramic implants—international  
magazine of ceramic implant technology. I would like to submit an article  
on the following topic:

---

---

Please send back your fax form or contact Mr. **Georg Isbaner**:  
g.isbaner@oemus-media.de · Phone: +49 341 48474-123

\_\_\_\_\_  
Last Name, First Name

\_\_\_\_\_  
Street/ZIP/City

\_\_\_\_\_  
Phone/E-Mail

\_\_\_\_\_  
Stamp

CI 1/18



# Clear trend towards metal-free reconstructions

**Dr Stefan Röhling is a fellow and speaker** of the International Team for Implantology (ITI) specialising on zirconia implant research. Georg Isbaner, editorial manager of *ceramic implants* interviewed Dr Röhling (Fig. 1) on his experience with ceramic implants, scientific research insights, market developments and perceived treatment chances and challenges with zirconia implants in comparison to titanium implants.

**Ceramic dental implants have already been known since their introduction in the late 1960s. However, titanium and titanium alloys are still the material of choice for most dental professionals. What do you assume to be the reasons?**

Titanium or titanium alloy implants are a reliable, scientifically well-investigated and popular treatment option

today, especially as the development from machined to micro-roughened titanium implant surfaces has constantly improved their clinical performance. The first ceramic implants were made of alumina and were clinically in use until the early 1990s. Based on poor biomechanical properties alumina could never be considered a reliable alternative to titanium. The first generation of zirconia implants was introduced at the beginning of the 2000s. Since then, manufacturing processes have constantly been improved to produce high-strength micro-rough zirconia implants with reliable biomechanical properties.

In summary, since the 1960s different materials were used for the fabrication of ceramic implants and various generations of zirconia implants have been rolled out



Fig. 1

**Fig. 1:** Dr Röhling at the IAOI World Congress 2017 in Miami, USA.

since the beginning of the 2000s. Many dental professionals are not aware of this fact and attribute the poor clinical performance of alumina implants in general to “ceramic implants”. It is important to realise that zirconia is a completely different material and that zirconia implants of the latest generation show similar clinical outcomes as titanium implants.

**When it comes to the scientific evidence, what do we know and where do we need to know more about ceramic implants?**

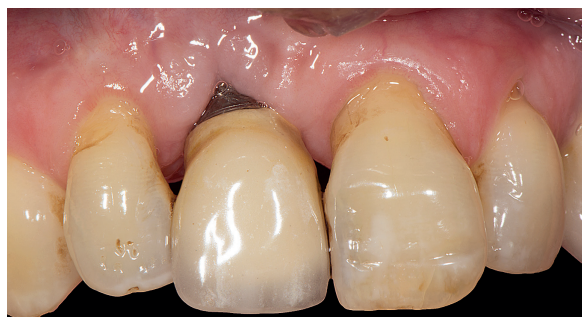Experimental studies have shown that zirconia implants of the newest generation have the ability to withstand oral forces and that artificial aging does not have any significant effect on the biomechanical long-term stability. Moreover, zirconia implants when compared to titanium implants show a similar capacity to integrate in bone as well as in soft tissue. In comparison to titanium or other metals, significantly reduced bacterial biofilm formation and reduced peri-implant soft tissue inflammation has been reported for zirconia. Clinically, survival rates of more than 95 per cent were reported for one-piece zirconia implants of the latest generation for investigation periods of up to five years. However, meta-analyses investigating clinical outcomes are limited to follow-up periods of only one year. Thus, a long-term status as known from titanium implants is currently not yet available. Moreover, only few clinical data is obtainable regarding the performance of two-piece zirconia implants.

**Zirconium, zirconium dioxide and zirconia: What are the differences?**

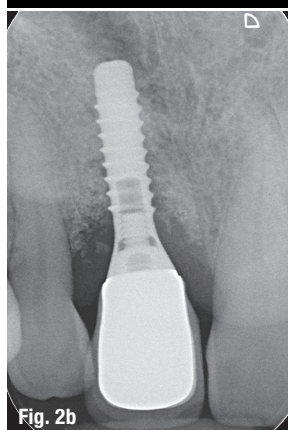
Zirconium is a pure metal characterised by a metallic bond and metal properties (e.g. free electrons and electrical conductivity). Zirconium dioxide, also called zirconia, is an oxide ceramic consisting of zirconium, oxygen and other supplements (e.g. yttria). Using ionic bonding, these different elements are firmly interconnected in a crystal lattice building a new class of material. Based on the characteristics of the ionic bond, there are localised electrons indicating typical ceramic properties like no electrical conductivity for zirconia.

**Zirconium dioxide is one of the toughest dental materials that exist. Can you explain in more detail what its capabilities are and what it means for the dental application, especially as implant material?**

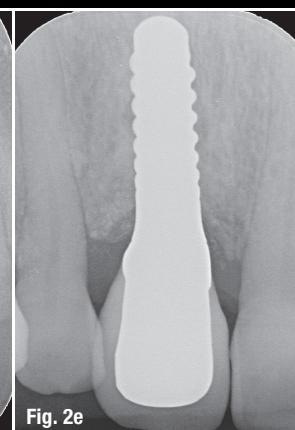
Compared to other ceramics, zirconia shows superior biomechanical properties like high fracture toughness and bending strength, giving zirconia implants the ability to withstand oral forces. In this context the “fracture toughening mechanism” of zirconia is very important. This mechanism can be considered as a self-healing process and describes the transition from a fracture proof tetragonal zirconia phase into a more fragile monoclinic zirconia phase. This tetragonal to monoclinic transi-



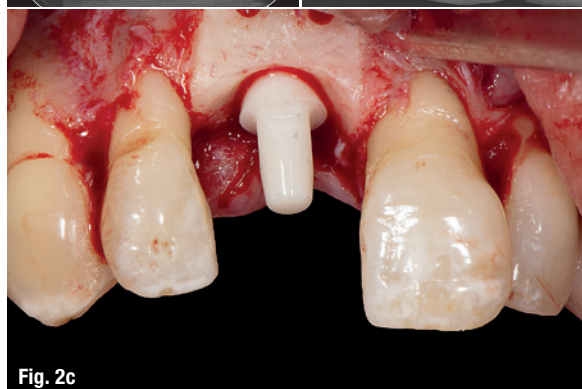
**Fig. 2a**



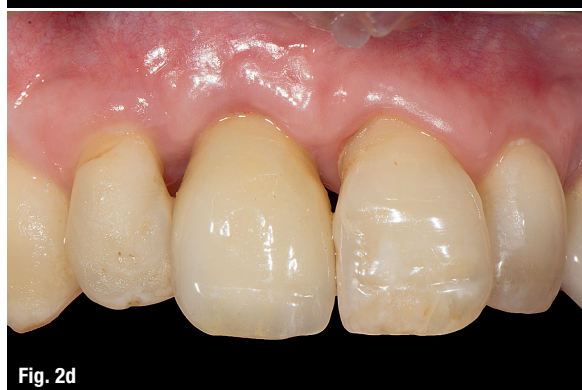**Fig. 2b**



**Fig. 2e**



**Fig. 2c**



**Fig. 2d**

**Fig. 2a:** Initial clinical situation after non-surgical peri-implantitis pretreatment. **Fig. 2b:** Radiograph showing evident peri-implant bone loss. **Fig. 2c:** Clinical situation at implant placement (PURE Ceramic Implant Monotype, Straumann) four months after implant removal and subsequent augmentation with autogenous bone. **Fig. 2d:** Clinical situation four weeks after cementation of definitive crown. **Fig. 2e:** Radiographic control at delivery of definitive crown.



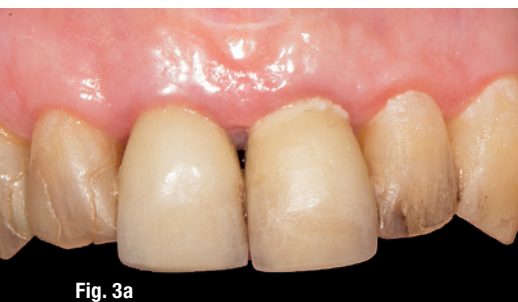

Fig. 3a

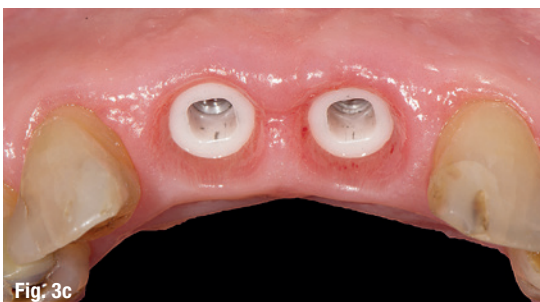

Fig. 3c

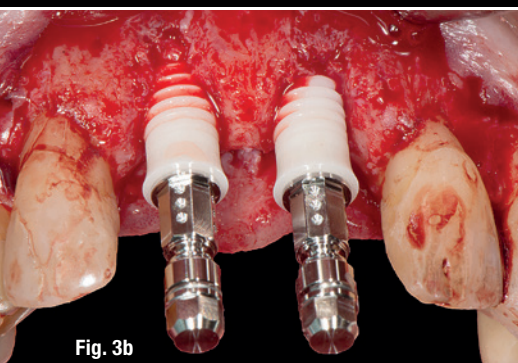


Fig. 3b

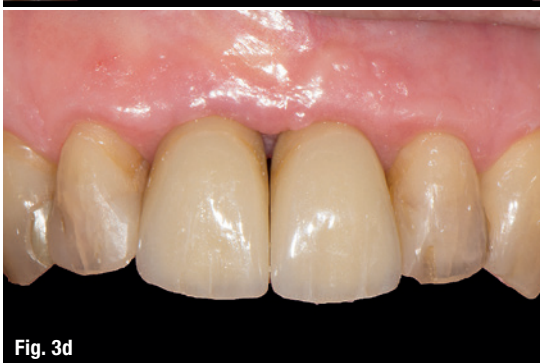

Fig. 3d

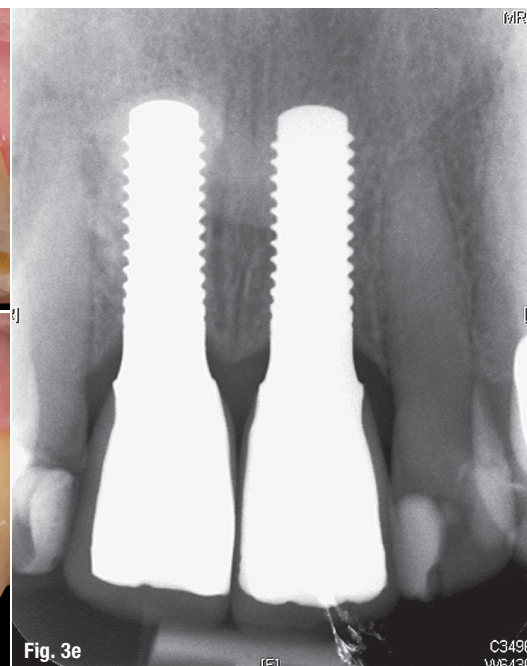


Fig. 3e

**Fig. 3a:** Initial clinical situation: Secondary root caries and longitudinal fractures in teeth #11 and #21 (implant location according to WHO). **Fig. 3b:** Clinical situation at implant placement eight weeks after tooth extraction. Two-piece zirconia implant (PURE Ceramic Implant, Straumann) with metal transfer piece. **Fig. 3c:** Clinical situation five months after implant placement. Delivery of definitive crown. **Fig. 3d:** Clinical situation at delivery of definitive screw-retained crown. **Fig. 3e:** Radiographic control at delivery of definitive crown.

tion is associated with a volume expansion which inhibits the propagation of mechanically induced micro-cracks in the material structure. Interestingly, uncontrolled implant surface treatment or grinding procedures might induce premature phase transformation, probably reducing the fracture toughening mechanism.

#### What medical indications do you recognise as the most suitable for ceramic implants?

In my opinion, there are no specific indications or contraindications for ceramic implants. Especially in the anterior region, ceramic implants might provide advantages over metal implants regarding pink and white aesthetics. Moreover, patients who do not want

“One-piece implants are the most natural and biological way to replace missing teeth.”

to be treated with metal implants, periodontally compromised patients and patients who have made bad experiences with titanium implants (e.g. implant loss caused by peri-implantitis) are highly relevant indication groups (Figs. 2a–e).

#### Regarding the surgical protocol and prosthetics how do ceramic implants differ from titanium implants?

In general, the surgical steps for placing zirconia implants do not differ from the protocols for titanium implants. While two-piece ceramic implants can be surgically handled similar to two-piece titanium implants, several special features should be considered when using one-piece implants.

Firstly, implant placement must be performed prosthetically driven to guarantee a correct implant axis. Further, only transgingival healing protocols might be applied and especially when implant placement was combined with bone augmentation procedures, overloading during the early healing phase has to be avoided, e.g. by protective stents or specifically adapted temporary prostheses. On the restorative side, there are less flexibilities for one- and two-piece ceramic compared to titanium implants.

#### In this respect, how important is the digital workflow when placing ceramic implants?

Especially when using one-piece ceramic implants, an adequate pre-surgical planning is evident since there are less possibilities on the restorative side to correct the implant axis and angulation compared to two-piece implant designs. Consequently, the digital workflow represents a very important tool for a serious backward planning in order to avoid incorrect implant positioning and angulation.



### What are the benefits of a one-piece and a two-piece ceramic implant system?

In my opinion, one-piece implants are the most natural and biological way to replace missing teeth. Since the abutment is an inherent part of the implant body, there are no micro-gaps on the abutment level. However, avoiding implant overloading during the early healing phase might be a challenge in larger edentulous or completely edentulous spaces. On the restorative side, there are less possibilities to correct a wrong implant axis whereas the prosthetics can only be cement-retained.

Regarding two-piece ceramic implants, the abutments and prosthetics can be cement- as well as screw-retained whereas a reliable screw-retained connection is still considered as a technical challenge for the manufacturers. Since individual abutments can be fabricated, there is more flexibility on the restorative side for two-piece compared to one-piece ceramic implants.

### What is the general patient awareness? Do they already know and explicitly ask about ceramic implants?

In dentistry, there is a clear trend towards metal-free reconstructions. In one of our latest studies we have found out that four times more patients would favour ceramic over titanium implants and that more than 50 per cent of the patients would even accept higher ceramic implant treatment costs. Obviously, without having detailed knowledge about dental implants, tooth-coloured ceramic implants are more attractive to patients than metal-coloured titanium implants. This fact has to be considered in the clinical daily routine. More and more patients will ask for ceramic implants and dental professionals must be prepared and informed to be able to give sound answers (Figs. 3a–e).

### Nowadays more and more companies are offering ceramic implants. How do you decide for a system, what is important for you?

The ceramic implant market has become quite confusing because of the many different generations of zirconia implants having been rolled out since the beginning of the early 2000s. The most critical factor is that not every zirconia implant system that is currently commercially available has been scientifically investigated. When deciding for an implant system, it must be mandatory that the offered zirconia implant and respectively the implant surface have been scientifically investigated in preclinical and clinical studies. These experimental data must not be exclusively based on internal test series from the manufacturers but should mainly be collected in independent scientific investigations. Moreover, implant companies must apply strict quality controls with regard to the manufacturing processes of zirconia implants.

### How important is the surface of the ceramic implant regarding the overall success when inserting ceramic implants?

The implant surface is one of the most critical factors for the achievement of a successful and long-lasting osseous integration. Owing to optimised manufacturing processes fracture-proof zirconia implants with a similar surface topography as micro-rough titanium implants can be produced. The development of micro-rough ceramic implant surfaces, such as the ZLA® surface (Straumann), must be considered as a main reason why zirconia implants of the latest generation have become a reliable treatment alternative showing similar survival rates compared to established titanium implants.

“Without having detailed knowledge about dental implants, tooth-coloured ceramic implants are more attractive to patients than metal-coloured titanium implants.”

### It has been suggested that with ceramic implants, surgeons can now treat patients that formerly refused to have an implant therapy with titanium implants. Do you agree?

Zirconia implants of the latest generation are a reliable and reasonable extension of the available treatment range of dental professionals. Thus, patients that formerly refused implant therapy with metallic titanium implants can now predictably be treated with ceramic implants.

**Dr Röhling, thank you for taking the time to answer our questions.**

### contact

#### Dr Stefan Röhling

ITI Fellow, Senior Oral Surgeon  
Assoc. Professor, University of Basel  
Röntgenstraße 10  
79539 Lörrach, Germany  
stefan.roehling@usb.ch



Author details

# A shift to “well-care”

**Dr Sammy Noubissi** has been practicing implantology for many years, specialising mainly on the use of ceramic implants. In 2011, Dr Noubissi founded the International Academy of Ceramic Implantology (IAOCI), an organisation dedicated exclusively to ceramic and metal-free alternatives to metal implants. In an interview with Georg Isbaner, editorial manager of *ceramic implants*, the IAOCI founder and president spoke about how he entered ceramic implant dentistry and how he approaches titanium versus ceramic and future challenges.

**Dr Noubissi, you are one of the leading dentists in the field of ceramic implantology having successfully organised the 7<sup>th</sup> IAOCI World Congress held in San Diego, USA, at the beginning of February. What were the most talked about aspects regarding zirconium dioxide implant systems?**

The 2018 congress was very successful and we reached our highest attendance ever: five continents and attendees from eighteen different countries were present. This year, three major aspects of ceramic implantology dominated the discussion. Firstly, a recurring theme among most speakers was the optimisation of patients' systemic health prior to implant surgery. Implant surgery requires optimal bone healing for initial implant integration and long-term success. The important role of Vitamin D, cholesterol levels, Vitamin C and Vitamin K in bone health and bone healing among others was widely discussed.

As a second aspect a few of our speakers introduced more advanced and complex cases with ceramic implants which clearly indicates that the limitations of ceramic implant applications are gradually disappearing. Thirdly, the correlation between peri-implantitis, certain systemic health problems and titanium disintegration as a result of corrosion was presented and supported with recently published research by Prof. Diane Daubert of the University of Washington and Dr Johan Lechner of Munich, Germany. We came out of this meeting with the overall understanding that ceramic implants are a viable alternative for aesthetic, functional and biological purposes. However, despite

the fact that there is mid-term clinical data available on various ceramic implant systems, there is still a need for structured and organised scientific research with ceramic implants.

**As it was your seventh IAOCI congress can you please describe how the discussion around ceramic implants has changed in comparison to the beginning of your IAOCI activities?**

There has been a steady evolution in the perception of ceramic implants and the discussions around them. In the early days their ability to integrate, the success rates and if they were really metal-free were questioned. Another source of discussion was their macroscopic design which was one-pieced and limited their range of application. Many of these concerns have been laid to rest today as we now have implants on the global market that are not only two-pieced but also contain metal-free abutment screws. Today there has been an added focus on the recipient of the implants and the correlation between their success and systemic health.

**Are there any therapeutic indications for which you recommend the use of ceramic implants only?**

Ceramic implants are a wonderful addition to the options implantologists and patients have in replacing lost or missing teeth. Like any other medical or dental modality, ceramic implants are not a panacea and certainly cannot be used exclusively. In terms of indications, we have seen the use of implants as a preferred method of tooth replacement grow exponentially. This has led to exposing a very broad range of individuals to dental implants, however, in return the biological response to these conventional implants has resulted in reevaluating the “biocompatible” label given to titanium and titanium alloy implants.

We now know from scientific literature that titanium when compared to zirconia ceramic did not fare as well in terms of aesthetics, plaque retention, epithelial attachment and soft tissue stability. We also know that ceramic implants with their unique surface treatments osseointegrate as well as titanium coated implants. I believe that ceramic implants when requested or offered should be used with consideration given to the biological factors such as immunology and, of course, the dental aspects also. Pa-

**Fig. 1** Founder of the International Academy of Ceramic Implantology (IAOCI) Dr Sammy Noubissi.

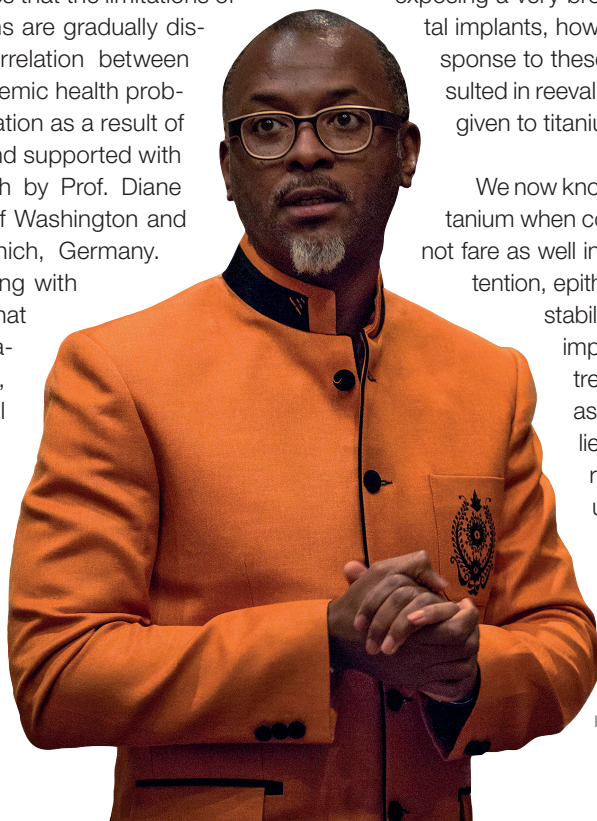

Photo: © IAOCI





Fig. 2

Fig. 2: Attendees at the 7<sup>th</sup> IAOI World Congress in San Diego, USA, on 15–17 February 2018.

tients and dentists who want superior aesthetic results as well as patients who have a history of allergies and sensitivity to metals are prime candidates for ceramic implants.

**In your opinion, what are the ideal properties and functions of a modern ceramic implant system?**

A modern ceramic implant—whether it's one-pieced or two-pieced—should be able to function as successfully as any conventional implant. Today, most ceramic implants do match the flexural strength of metal alloys although there are some ceramic composites headed to the market that will address such concerns in a significant manner. Another important thing is that implants, especially from a prosthetic aspect, need to be versatile, meaning they have to be easily serviceable. I see manufacturers coming out with screw-retained two-piece ceramic implants now and even metal-free screws, which is exciting.

**When do you use a one-piece ceramic implant, and what are the indications for a two-pieced system?**

When I fully entered ceramic implantology, the only option available in North America where I practice were one-piece ceramic implants. We managed to treat about 90 per cent of cases that came to our clinic. The greatest challenge was the precise and accurate placement of the implant as there are very few systems that allow you to prep their abutment if you are off by a couple degrees. However, I was able to treat a wide range of cases from single implants to full-mouth reconstructions.

In the last four or five years, having two-piece ceramic implants with cementable or screw-retained abutments has brought options to a whole new level as there are more options and more flexibility. As I see it I would recommend using one-piece ceramic implants for single tooth or multiple separate single teeth replacement mainly in the molar and premolar area. When it comes to anterior teeth or full arches, although in some cases one-piece implants will work, I prefer a two-piece solution. For servicing and maintenance, I recommend two-pieced, screw-retained, and in keeping with the metal-free philosophy using a system that offers a metal-free screw.

**Drawing from your experience, do you think patients who oppose titanium implants decide now in favour of ceramic implant solutions?**

Yes, absolutely. In my experience when I discuss treatment with patients and I present the option of a metal-free implant, I get approximately 93 per cent who would prefer a metal-free solution and 80 per cent of these are willing to spend extra to replace their teeth with ceramic implants instead of titanium. The reason for that in my opinion is that people have become more and more health conscious and concerned with the type of treatment they are willing to accept. Just look at the proliferation of organic/biologic supermarkets and the rise of alternative medicine, biological dentistry and integrative medicine. There is a shift from old fashioned health/dental care to what I like to call “well-care”.

**What are the future challenges or tasks of ceramic implant technologies?**

Ceramic implants still need to improve in terms of flexural strength, their structural and biological properties however are far superior to metals. Ceramic implants are not vulnerable to corrosion, do not release ions in the host and should be regarded as the most biocompatible dental implant material available today. Continued research and development are the key, but also close collaboration with clinicians who see far more and unfortunately report less than researchers.


Dr Noubissi, thank you very much.

**contact**

**Dr Sammy Noubissi**

DDS, MS, PA  
Practice limited to Metal-Free  
Dental Implantology  
801 Wayne Avenue, Suite #G200  
Silver Spring, MD 20910, USA  
drsammy@milesforsmile dental.net

Author details





# “The future of implantology—ceramics and biology” in Hamburg

On 22 and 23 June 2018 the International Society of Metal Free Implantology (ISMI) is hosting its 4<sup>th</sup> Annual Meeting in the Hanseatic City of Hamburg, Germany. Participants can anticipate seminars, live surgeries and an interesting presentation programme.

**ISMI** | INT. SOCIETY  
OF METAL FREE  
IMPLANTOLOGY



The 4<sup>th</sup> Annual Meeting of the International Society of Metal Free Implantology (ISMI), taking place on the second last weekend of June 2018, will be focused on the topic: “The future of implantology—ceramics and biology”. International speakers and participants will be discussing practical experience and current trends in the use of ceramic implants during both congress days at the EMPIRE RIVERSIDE HOTEL Hamburg.

Also with its 4<sup>th</sup> Annual Meeting, ISMI, founded in Constance, Germany, in January 2014, is once again intending to set examples in the especially innovative field of implantology. After a successful inaugural event in 2015 and the international annual congresses 2016 in Berlin and 2017 in Constance ISMI is now inviting to Hamburg on 22 and 23 June 2018. The team of speakers at the ISMI congress will once again include national and international experts. On Friday, the two-day event will

be starting with pre-congress symposia and live surgery broadcasts via Internet. The ISMI White Night will be the highlight of the first congress day, offering participants the opportunity to enjoy culinary specialties in a relaxed and stylish atmosphere. Saturday will be focused on scientific presentations and again include topics of all fields of metal-free implantology.

The International Society of Metal Free Implantology (ISMI) was founded in order to promote metal-free implantology as an innovative and especially visionary path of implantology. ISMI is therefore supporting its members with regular further education offers as well as regular expert and market information. ISMI is further focusing on establishing metal-free treatment concepts of implantology through its public relations efforts in specialist groups and patient communication. ISMI members will receive a 20 per cent discount on the congress fee.

## contact

### OEMUS MEDIA AG

Holbeinstraße 29  
04229 Leipzig, Germany  
Tel.: +49 341 48474-308  
event@oemus-media.de  
www.oemus.com  
www.ismi-meeting.com



# 4<sup>TH</sup> ANNUAL MEETING OF **ISMI** | INT. SOCIETY OF METAL FREE IMPLANTOLOGY



22–23 June 2018

**Hamburg, Germany — EMPIRE RIVERSIDE HOTEL**

BOOK ONLINE /  
CONGRESS PROGRAM



[www.ismi-meeting.com](http://www.ismi-meeting.com)

## Theme

**The future of implantology—Ceramics and Biology**

## Scientific Director

**Dr Karl Ulrich Volz/Kreuzlingen (CH)**

## Premium Partner

**camlog**

**SDS** SWISS DENTAL  
SOLUTIONS

## PRE-CONGRESS

**FRIDAY, 22 June 2018**

### SYMPOSIUM 1

09:30–12:00

**SDS** SWISS DENTAL  
SOLUTIONS

**Ceramic, in any case—Why different implant designs are the key to a successful surgery**

**Dr Dominik Nischwitz/Tübingen (GER)**

### LIVE SURGERY (Live streaming)

**Bone growing implants—intelligent use of biological laws**

As part of the regeneration of dissolved bone, bone regeneration follows irrevocably biological laws. The creation of cavities by so-called spacemakers in combination with the forming of a blood clot is a long-known procedure for guided bone regeneration (GBR). This live surgery, combined with a webinar, introduces an autologous therapy concept for guided regeneration of lamellar bone tissue which is based on the longstanding tent-pole-sunshade principle and requires no bone replacement material.

**Dr Karl Ulrich Volz/Kreuzlingen (CH)**

12:00–13:00

Break/Visit of the Dental Exhibition

### SYMPOSIUM 2

13:00 – 15:00

**camlog**

**Introducing CERALOG implant systems—components and indications**

**Case presentation with regard to the live surgery**

**Dr Sandra Wagner/Dortmund (GER)**

### LIVE SURGERY (Live streaming)

**Template-supported anatomically inserted soft tissue shaping**

Backward planning is indispensable for the successful reconstruction with implants. Apart from the three-dimensional imaging of the jawbone and its adjacent anatomic structures, virtual implant planning is increasingly used. Based on the available data, individual CAD/CAM gingiva formers made of zirconium dioxide are being manufactured in advance to shape the soft tissue in the aesthetic area. In this live surgery, the two-piece CERALOG implants are being precisely positioned in the aesthetic area by using a drilling template. In addition, individual healing abutments are being inserted. This treatment option, combined with an interdisciplinary exchange, leads to a predictable outcome.

**Dr Rouven Wagner/Dortmund (GER)**

### Discussion and questions

**Dr Sandra Wagner, Dr Rouven Wagner/Dortmund (GER)**

15:00 – 15:30

Break/Visit of the Dental Exhibition

### PRE-CONGRESS SESSION

**Moderation** Dr Dominik Nischwitz/Tübingen (GER)

### Case presentations

15:30 – 15:55  
Lecture partly in English  
(Simultaneous translation)

**Dr Manuel Bras da Silva/Dortmund (GER)**

**Dr Peter Fairbairn/London (UK)**

A new bioresorbable bone regeneration material for the augmentation in immediate and delayed loading with ceramic implants

15:55 – 16:20

**Christoph Arlom/Berlin (GER)**

14 years of experience with ceramic implants—possibilities and restrictions—A practice concept

16:20 – 16:45

**Dr Robert Bauder, M.Sc., M.Sc./Kitzbühel (AT)**

Ceramic implants as a successful immunological door opener for patients with titanium intolerance

16:45 – 17:10

Lecture in English  
(Simultaneous translation)

**Dr Sammy Noubissi/Silver Spring (US)**

Treatment planning and Case-Specific Implant System selection with Ceramic Implants

17:10 – 17:35

Lecture in English  
(Simultaneous translation)

**Dr Stuart Molloy/Paris (FR)**

How to enhance your office with a full zirconium implant and prosthetic rehabilitation by thinking outside the box

17:35 – 18:00

**Dr Armin Nedjat/Flonheim (GER)**

Why the (R)EvoBio pZircono manages to achieve a change of paradigm in the MIM procedure

18:00 – 18:15

### Panel discussion

under the direction of Dr Dominik Nischwitz/Tübingen (GER)

Simultaneous translation German/English, English/German

from 19:30

### EVENING EVENT | ISMI WHITE NIGHT

## MAIN CONGRESS

**SATURDAY, 23 June 2018**

**Scientific leadership/moderation** Dr Karl Ulrich Volz/Kreuzlingen (CH)

09:00 – 09:10

**Dr Karl Ulrich Volz/Kreuzlingen (CH)**

Greeting and opening



## Biological dentistry and ceramic implants

09:10 – 09:40

**Dr Dominik Nischwitz/Tübingen (GER)**  
Vitamin D3 and other important micronutrients as a guarantee for success in osseointegration with ceramic implants

09:40 – 10:10

Lecture in English  
(Simultaneous translation)

**Prof. Dr Jose Mendonca-Caridad/Santiago di Compostela (ES)**  
The maxilla and mandible as a major source of toxicity: surgical and systemic approaches with zirconia implants

10:10 – 10:40

**Dr Carolin Stolzer/Hamburg (GER)**  
Immunological reaction to titanium implants/ceramic implants

10:40 – 11:00

Discussion

11:00 – 11:30

Break/Visit of the Dental Exhibition

## Science

11:30 – 12:00

**Univ.-Prof. Dr Dr Ralf Smeets/Hamburg (GER)**  
Bioactivation of ceramic implants through UV light and nonthermal plasma—an in vitro and in vivo study—a new path in implantology?

12:00 – 12:30

Lecture in English  
(Simultaneous translation)

**Elisa Choukroun/Nice (FR)**  
Prevention of oxidative stress in surgery

12:30 – 12:45

Discussion

12:45 – 13:30

Break/Visit of the Dental Exhibition

## Hard and soft tissue on ceramic implants

13:30 – 14:00

**Dr Frederic Hermann, M.Sc./Zug (CH)**  
Ceramic implants at the focus of soft tissue biology

14:00 – 14:45

Lecture in English  
(Simultaneous translation)

**Dr Alain Simonpieri/Beausoleil (FR)**  
Modern approach of full arch immediate loading

14:45 – 15:30

**Sabine Hufilz/Chemnitz (GER)**  
Sinus lifts with ceramic implants—according to biological legitimacy

15:30 – 16:00

Break/Visit of the Dental Exhibition

16:00 – 16:45

**Dr Karl Ulrich Volz/Kreuzlingen (CH)**  
Bone Growing Implants

16:45 – 17:15

**Dr Alexander Neubauer/Tittling (GER)**  
The biological treatment concept and ceramic implants—practical implementation of a new vision

## ORGANISATIONAL MATTERS

### Congress Fees

**Friday, 22 June 2018 | Pre-Congress**

€ 195 plus VAT

(Participation Pre-Congress Symposia & Session)

**Saturday, 23 June 2018 | Main Congress**

Dentists

€ 260 plus VAT

**Friday, 22 June & Saturday, 23 June 2018**

Dentists

€ 420 plus VAT

Assistants (with verification)

€ 135 plus VAT

Conference charge\* (per days)

€ 59 plus VAT

ISMI members receive 20 % discount on the congress fee on Saturday!

### Team programme | Hygiene seminar

Dentists

€ 275 plus VAT

Helper

€ 224 plus VAT

Team Price (ZA + ZAH)

€ 448 plus VAT

Conference charge\* (both days, per person)

€ 118 plus VAT

\* The conference charge is to be paid by each participant and includes coffee breaks, conference drinks and lunch.

### Evening event | ISMI WHITE NIGHT

In the Au Quai restaurant with conservatory and private terrace!

**Friday, 22 June 2018, from 19:30**

Price per person

€ 120 plus VAT

The price includes food and drinks.

### Venue

EMPIRE RIVERSIDE HOTEL  
Bernhard-Nocht-Straße 97  
20359 Hamburg | Germany  
www.empire-riverside.de



### Room booking in various categories

Tel.: +49 211 49767-20 | Fax: +49 211 49767-29

wolters@primecon.eu | www.primecon.eu

### Organiser

ISMI – International Society of Metal Free Implantology  
Lohnerhofstraße 2 | 78467 Constance | Germany  
Tel.: +49 800 4764-000 | Fax: +49 800 4764-100  
office@ismi.me | www.ismi.me

### Organisation/Registration

OEMUS MEDIA AG  
Holbeinstraße 29 | 04229 Leipzig | Germany  
Tel.: +49 341 48474-308 | Fax: +49 341 48474-290  
event@oemus-media.de | www.oemus.com

OEMUS MEDIA AG

4<sup>TH</sup> ANNUAL MEETING OF  
**ISMI** | INT. SOCIETY  
OF METAL FREE  
IMPLANTOLOGY

Please fax this registration form to  
**+49 341 48474-290**

OEMUS MEDIA AG  
Holbeinstraße 29  
04229 Leipzig  
Germany

I hereby register the following person for the **4<sup>th</sup> Annual Meeting of ISMI** from 22–23 June 2018 in Hamburg, Germany.  
(Please fill out/tick as appropriate):

	<input type="checkbox"/> Friday	<input type="checkbox"/> Hygiene seminar
	<input type="checkbox"/> Saturday	
Last Name, First Name, Activity	Programme dentists	Team programme
ISMI member <input type="checkbox"/> yes <input type="checkbox"/> no		

	<input type="checkbox"/> Friday	<input type="checkbox"/> Hygiene seminar
	<input type="checkbox"/> Saturday	
Last Name, First Name, Activity	Programme dentists	Team programme
ISMI member <input type="checkbox"/> yes <input type="checkbox"/> no		

Evening event (Friday, 22 June 2018) \_\_\_\_\_ (Please enter number of persons.)

Stamp

I hereby accept the terms and conditions of the OEMUS MEDIA AG.

Date, Signature

E-mail address (Please specify! You will receive invoice and certificate by e-mail.)

## Biofilm research could advance

### Development of dental materials

Biofilms are generally regarded as a problem to be eliminated due to the threats they pose to humans and materials. However, new research suggests that communities of algae, fungi or bacteria possess interesting properties from both a scientific and technical perspective. These properties could result in the improved creation of structural templates, including materials for teeth.

All natural materials (whether wood, bone or teeth) have been optimised by evolution over millions of years according to the principle of adapted stability with the lowest possible weight. Thus, nature provides the blueprints for many technical developments. The structural complexity of the original material in nature can however often not be reproduced, as the processes on the nanometer scale are hard to evaluate and mimic.

Prof. Cordt Zollfrank and his team of researchers at the Chair of Biogenic Polymers at the Technical University of Munich, Campus Straubing for Biotechnology and Sustainability, have now presented



© Amnuay.J/Shutterstock.com

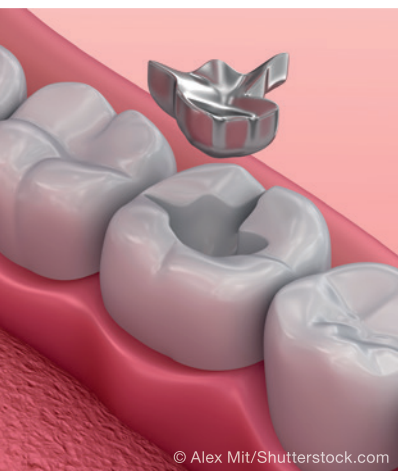a series of biological procedures that use light, heat, specially-prepared substrates and other stimuli to direct the movement of microorganisms along specific paths.

The findings make it possible to create tailor-made templates for new materials with natural structures from the microbes themselves, or their secretions. The scientists are already applying some of these methods aiming at profiting of the special properties of red algae to create long, fine polymer threads that serve as customised templates for the manufacturing of functional ceramics.

**Source: Technical University of Munich**

## Cancer-inducing effects of

### Metal used intraorally



© Alex Mit/Shutterstock.com

US researchers investigated the possible risk factors for carcinoma in the oral cavity—the cancer causing effects of alcohol and smoking have multiply been researched already and such consumptions have indisputably been found to be an important trigger for oral cancer. Nevertheless, there are numerous cases in which they are not consumed. The researchers of the University of Chicago have thus decided to investigate, proposing that metals used in the mouth as tooth replacement or during orthodontic

treatments also have cancer-inducing effects.

54 cancer patients with the fitting precondition participated in the study, of whom 80 per cent had never smoked and 20 per cent only sporadically. No participant had more than two alcoholic drinks per week, 80 per cent even consuming a maximum of only one. All patients had however in one way or another been exposed to metallic materials in the mouth.

It was found, that 40 patients had received tooth replacements containing metal prior to being diagnosed with cancer. The study while determining first indications could, however, not yet prove a causal connection between cancer of the oral cavity and dental materials containing metal.

**Source: ZWP online**

## Cavitating jets improve

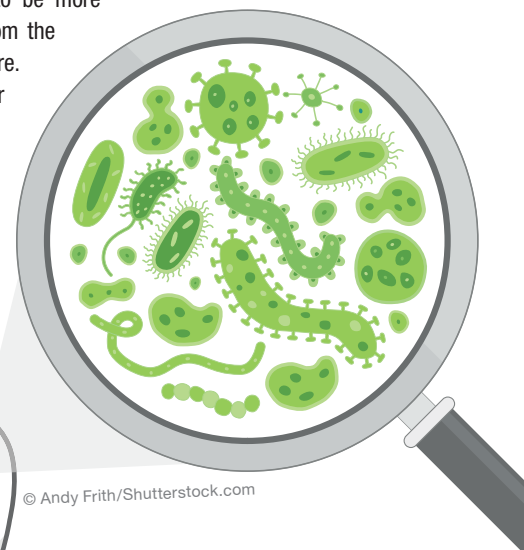### Removal of oral biofilm

In their recent study, “Removal of oral biofilm on an implant fixture by a cavitating jet”, Prof. Hitoshi Soyama from Tohoku University and his team from Showa University searching for better ways for dentists to remove plaque from implant fixtures compared the effects of a cavitating jet to the standardly used water jet. With the cavitating jet, high-speed fluid is injected by a nozzle through water to create minuscule vapour bubbles, which in collapsing produce shock waves with sufficient force to remove surface contaminants.

To test the two jets, four volunteers performed no oral care for three days to allow biofilm to develop. Their fixtures were then cleaned using both methods, with the Japanese researchers measuring the amount of plaque remaining at several time intervals.

They found the cavitating jet to be more effective in removing biofilm from the rough surface of an implant fixture.

In addition to the water jet's shear effect, the cavitating jet produces considerable force when the bubbles collapse. Both processes in synergy thus make the cavitating jet superior when cleaning plaque off the irregular surface of dental implants.



© Andy Frith/Shutterstock.com



# Congresses, courses and symposia



## EuroPerio9

20–23 June 2018

Venue: Amsterdam, Netherlands  
[www.efp.org/europerio9](http://www.efp.org/europerio9)



## 4th Annual Meeting of ISMI

22–23 June 2018

Venue: Hamburg, Germany  
[www.ismi.me](http://www.ismi.me)



## Visions in Implantology— 1st Future Congress for Dental Implantology

28–29 September 2018

Venue: Düsseldorf, Germany  
[www.dgzi-jahreskongress.de](http://www.dgzi-jahreskongress.de)



## EAO Congress 2018

11–13 October 2018

Venue: Vienna, Austria  
[www.eao.org](http://www.eao.org)



## Giornate Veronesi

03–04 May 2019

Venue: Verona, Italy  
[www.giornate-veronesi.info](http://www.giornate-veronesi.info)

# ceramic implants

international magazine of ceramic implant technology

## Imprint

### Publisher

Torsten R. Oemus  
[oemus@oemus-media.de](mailto:oemus@oemus-media.de)

### CEO

Ingolf Döbbecke  
[doebbecke@oemus-media.de](mailto:doebbecke@oemus-media.de)

### Members of the Board

Jürgen Isbaner  
[isbaner@oemus-media.de](mailto:isbaner@oemus-media.de)

Lutz V. Hiller

[hiller@oemus-media.de](mailto:hiller@oemus-media.de)

### Editorial Manager

Georg Isbaner  
[g.isbaner@oemus-media.de](mailto:g.isbaner@oemus-media.de)

### Editorial Office

Katharina Rühling  
[k.ruehling@oemus-media.de](mailto:k.ruehling@oemus-media.de)

### Executive Producer

Gernot Meyer  
[meyer@oemus-media.de](mailto:meyer@oemus-media.de)

### Product Manager

Timo Krause  
[t.krause@oemus-media.de](mailto:t.krause@oemus-media.de)

### Art Director

Alexander Jahn  
[a.jahn@oemus-media.de](mailto:a.jahn@oemus-media.de)

### Designer

Sandra Ehnert  
[s.ehnert@oemus-media.de](mailto:s.ehnert@oemus-media.de)

Theresa Weise

[t.weise@oemus-media.de](mailto:t.weise@oemus-media.de)

### Customer Service

Marius Mezger  
[m.mezger@oemus-media.de](mailto:m.mezger@oemus-media.de)

### Published by

OEMUS MEDIA AG  
Holbeinstraße 29  
04229 Leipzig, Germany  
Tel.: +49 341 48474-0  
Fax: +49 341 48474-290  
[kontakt@oemus-media.de](mailto:kontakt@oemus-media.de)

### Printed by

Silber Druck oHG  
Am Waldstrauch 1  
34266 Niestetal, Germany

**[www.oemus.com](http://www.oemus.com)**



## Copyright Regulations

ceramic implants international magazine of ceramic implant technology is issued twice per year and is a special edition of **implants international magazine of oral implantology** — the first issue was published in October 2017. The magazine and all articles and illustrations therein are protected by copyright. Any utilisation without the prior consent of editor and publisher is inadmissible and liable to prosecution. This applies in particular to duplicate copies, translations, microfilms, and storage and processing in electronic systems.

Reproductions, including extracts, may only be made with the permission of the publisher. Given no statement to the contrary, any submissions to the editorial department are understood to be in agreement with a full or partial publishing of said submission. The editorial department reserves the right to check all submitted articles for formal errors and factual authority, and to make amendments if necessary. No responsibility shall be taken for unsolicited books and manuscripts. Articles bearing symbols other than that of the editorial department, or which are distinguished by the name of the author, represent the opinion of the aforementioned, and do not have to comply with the views of OEMUS MEDIA AG. Responsibility for such articles shall be borne by the author. Responsibility for advertisements and other specially labelled items shall not be borne by the editorial department. Likewise, no responsibility shall be assumed for information published about associations, companies and commercial markets. All cases of consequential liability arising from inaccurate or faulty representation are excluded. General terms and conditions apply, legal venue is Leipzig, Germany.

# SUBSCRIBE NOW!

ceramic implants—international magazine of ceramic implant technology

Interdisciplinary, transparent & market orientated

ONLINE  
SUBSCRIPTION HERE



www.oemus-shop.de



## stay updated:

research  
**Guided regeneration  
of lamellar bone tissue**

case report  
**Immediate placement  
in the aesthetic zone**

interview  
**Clear trend towards  
metal-free reconstructions**

Fax: **+49 341 48474-290**

I would like to subscribe for the following journals:

- ☐ ceramic implants—international magazine of  
ceramic implant technology 2 issues p.a. € 30\*
- ☐ implants—international magazine of oral implantology 4 issues p.a. € 44\*

Terms & Conditions: The subscription may be cancelled in written form without due justification within 14 days of order by contacting OEMUS MEDIA AG, Holbeinstraße 29, 04229 Leipzig, Germany. Dispatching notification in good time will suffice. The subscription is automatically extended by another twelve months if it is not cancelled in written form 6 weeks prior to the end of the reference period.

\* All prices include VAT, shipping and handling (within Germany).

\_\_\_\_\_  
Last Name, First Name

\_\_\_\_\_  
Company

\_\_\_\_\_  
Street

\_\_\_\_\_  
ZIP/City/Country

\_\_\_\_\_  
E-Mail

\_\_\_\_\_  
Signature

\_\_\_\_\_  
Credit Card Number

\_\_\_\_\_  
Expiration Date

\_\_\_\_\_  
Security Code



CERAMIC EXCELLENCE

CERALOG<sup>®</sup>  
SYSTEM

# INVISIBLE



**Perfect red-white esthetics, supported by tooth-like coloring and the properties of zirconium oxide – that is CERAMIC EXCELLENCE.**

- Dual surface texture: Osseointegration and soft tissue attachment
- Two-piece design, screw-retained reversible prosthetic solutions
- Ceramic-specific design with Hexalobe connection
- Innovative PEKK abutment with stress shield reduction
- Ivory colored for highly esthetic restorations
- 100 % quality control



Become a  
CERAMIC EXCELLENCE  
partner now  
[www.camlog.com/en/implant-systems/ceralog](http://www.camlog.com/en/implant-systems/ceralog)

CERAMIC-SPECIFIC  
DESIGN WITH  
HEXALOB  
CONNECTION



a perfect fit™

camlog